

**“LUCIAN BLAGA” UNIVERSITY OF SIBIU**

**FACULTY OF MEDICINE**

**DENTAL FOCAL INFECTION IN  
ANTERIOR UVEITIS PATHOLOGY**

**(Summary of PhD thesis)**

**Doctoral advisor:**

**Professor Adriana Stănilă, MD, PhD**

**PhD candidate:**

**Adriana Săceleanu, MD**

**SIBIU**

**2015**

## TABLE OF CONTENTS

LIST OF ABBREVIATIONS.....	I
----------------------------	---

INTRODUCTION.....	II
-------------------	----

### *GENERAL PART*

<b>CHAPTER 1 .....</b>	<b>1</b>
------------------------	----------

MORPHOPHYSIOLOGY OF THE ODONTON AND THE UVEA .....	1
--	---

1. THE ODONTON .....	1
----------------------	---

1.1.THE ODONTIUM .....	1
------------------------	---

1.1.1. The enamel .....	2
-------------------------	---

1.1.2. The dentin.....	4
------------------------	---

1.1.3. The dental pulp.....	6
-----------------------------	---

1.2.THE PERIODONTIUM.....	7
---------------------------	---

1.2.1. The gum.....	8
---------------------	---

1.2.1.1. The gingival epithelium .....	9
--	---

1.2.1.2. The gingival corium .....	10
------------------------------------	----

1.2.1.3. The supra-alveolar ligament system.....	10
--	----

1.2.2. The root cementum.....	10
-------------------------------	----

1.2.3. The alveolar bone .....	11
--------------------------------	----

1.2.4. The desmodontium .....	13
-------------------------------	----

2. THE UVEA.....	14
------------------	----

2.1. The iris.....	14
--------------------	----

2.2. The cyliary body.....	16
----------------------------	----

2.3. The choroid .....	19
------------------------	----

<b>CHAPTER 2 .....</b>	<b>20</b>
------------------------	-----------

DENTAL FOCAL DISEASE.....	20
---------------------------	----

GENERALITIES .....	20
--------------------	----

2.1. DENTAL FOCAL DISEASE .....	20
---------------------------------	----

2.1.1. Definition of dental focal disease.....	20
--	----

2.1.2. Characteristics of dental focal disease .....	20
--	----

2.1.3. Localization of the focal deseases .....	21
---	----

2.1.4. Classification of focal diseases in the oral cavity .....	22
--	----

2.1.4.1. Primary focal infections .....	22
---	----

2.1.4.2. Secondary focal infections .....	27
---	----

2.1.5. Etiopathogeny of focal disease.....	27
--	----

2.1.6. Clinical signs .....	29
-----------------------------	----

2.1.7. Diagnostic of focal disease.....	29
---	----

<b>CHAPTER 3 .....</b>	<b>34</b>
------------------------	-----------

UVEITIS .....	34
---------------	----

3.1. Definition of uveitis .....	34
----------------------------------	----

3.2. Classification of uveitis .....	34
--------------------------------------	----

3.3. Clinical picture of uveitis .....	38
3.4. Uveitis treatment .....	41

***PERSONAL RESEARCH PART***

<b>CHAPTER 4 .....</b>	<b>45</b>
------------------------	-----------

MOTIVATING FOR THE CHOICE OF THE THEME

<b>CHAPTER 5 .....</b>	<b>47</b>
------------------------	-----------

PURPOSE OF THE PAPER

<b>CHAPTER 6 .....</b>	<b>48</b>
------------------------	-----------

MATERIALS AND METHODS

<b>CHAPTER 7 .....</b>	<b>62</b>
------------------------	-----------

RESULTS INTERPRETATION

<b>CHAPTER 8 .....</b>	<b>134</b>
------------------------	------------

CASE STUDIES

<b>CHAPTER 9 .....</b>	<b>160</b>
------------------------	------------

DISCUSSIONS

<b>CHAPTER 10 .....</b>	<b>169</b>
-------------------------	------------

CONCLUSIONS

<b>BIBLIOGRAPHY .....</b>	<b>173</b>
---------------------------	------------

**Keywords:** uveitis, inflammation, focal disease, dental focal infection.

# INTRODUCTION

Focal infection is a chronic inflammatory process (oligosymptomatic or asymptomatic) with periodic exacerbations, localized, well-defined biologically with pathogenic potential over time.

Focal dental disease is a pathological condition of the body, clinically manifested at organ or system level, characterized by functional disorders or organ damage, which can be attributed only to the presence in the body of chronic focal infections.

Of the many focals that can cause a “focal infection”, a well-defined special place is occupied by odontal and periodontal infections, because these in turn can cause major repercussions on the health of the entire body.

Numerous etiopathogenic theories have been formulated as assumptions of the occurrence of symptoms at distance due to chronic focal infections: germ, allergic, toxic, vascular, psychosomatic theories. It is difficult to specify which of these mechanisms are responsible for the various pathological manifestations of the focal infection. Etiopathogeny is complex and etiological diagnosis is difficult. Focal disease manifests through local and general signs and can be treated through close cooperation between several medical specialties: dentistry, ophthalmology, ENT, cardiology.

After eradicating focal infections, nonallergic, allergic, hyperergic phenomena are improved or disappear completely. What remains after the removal of the focal infection is the altered reactivity of the body with symptoms that have the character of a local inflammation.

In 2008, the International Uveitis Study Group (IUSG) designed a simplified, clinical classification system for uveitis based on etiological criteria. Therefore, there are 3 main categories, as follows: infectious (e.g., bacterial, viral, fungal, parasitic), noninfectious (e.g., known systemic associations, no known systemic associations), and masquerade (e.g., neoplastic, nonneoplastic).[111]

The Standardization of Uveitis Nomenclature (SUN) Working Group met in 2009 to standardize the descriptions and terminologies necessary to develop tools, such as computerized data entry forms and classification criteria. Initial terminology was developed via Web-based surveys, broadband Delphi techniques, and teleconferences. This terminology

was then revised by workshop participants using nominal group techniques and supermajority voting. A total of 193 terms were identified and mapped to 28 major uveitic disease entities.[112,113]

In this paper, I aim at studying the association between uveal pathology and the presence of dental infections, as well as the importance of the histopathologic examination of the biological product obtained after dental treatment with a view to adopt appropriate therapeutic treatment.

I would like to thank Professor Adriana Stănilă, MD, PhD, the coordinator of this PhD thesis for the support in developing scientific rationale and for the impeccable academic guidance.

I also wish to thank my colleagues from the dental centre and the team of the anatomical-pathology laboratory for help and advice given to select the patients who finally represented the study subjects.

We hope that this paper will contribute to the vast field of anterior uveitis therapy and interdisciplinary collaboration, so that patients receive appropriate treatment whose ultimate goal will result in their socio-professional reinsertion.

## **GENERAL PART**

### **Chapter 1. Morphophysiology of odonton and uvea**

This chapter provides anatomic and physiologic data underlying tooth structure and uvea. Their knowledge is very important for an accurate diagnosis and appropriate treatment.

**The tooth** together with its auxiliary system is a morphological and functional unit, which we call the dental organ or odonton [1]. The morphological and functional complex consists of the tooth, the portion of alveolar bone surrounding the tooth root and the periodontal space contents (structures that actually secure and support the teeth: alveolar bone, dental cementum, gum, periodontium).

Although each of them has different structures, functional mutual relations exist between them. Functional interrelations at the level of odonton result in the establishment of a unitary system, the result being the integration of the tooth in the rest of the body [2].

**The uvea** is the average tunic of the eye being placed between the outer fibrous tunic, composed of the cornea and sclera, the nervous tunic being located in the interior, consisting

of the retina. Being made up of mesodermal tissue, uvea acts as a real vascular sponge playing mainly the role of ensuring eyeball nutrition. Given its nutritional role, any suffering of uvea will affect the structures of the eyeball, the most affected being the retina [52]. Participation of aqueous humor and vitreous body to uveal inflammation should not be neglected. The uvea is composed of three distinct parts: iris, ciliary body, choroid.

## Chapter 2. Dental focal infection

This chapter contains data on the focal infection, location and classification of dental focal diseases, diagnosis and clinic of dental focal infections. Since 1990, the term of “focal infection” was associated to some extremely varied pathological manifestations involving the entire body or only some organs, originating in a chronic focal infection. From this level, there are hematogenously disseminated, continuously or intermittently: antimicrobial agents, toxins, allergens. Through the diffusion of microbes, toxins and allergens, there occur in the organism multiple focal infections with different seniority, characterized by histiocytic reactions [57]. The proper name is “focal disease”, the original name of “focal infection” being outdated, taking into account the large number of symptoms at distance. **Focal disease** is a pathological condition, characterized by a large variety of functional disorders and organic tissue alterations due to chronic focal infections, which episodically and through blood, nervous or digestive systems, various microbes, microbial toxins, toxic products of tissue septic disintegration, endo- or exogenous allergens are disseminated into the organism, generating a vast array of dysfunctional and lesional events. Diagnosis of the focal disease is a significant, difficult issue in the medical practice, because there should be stated whether the pathological manifestations are determined by the disease itself or as a result of the existence of chronic focal infections. Their detection and treatment must be carried out by a joint team mandatorily made up of an internist and other specialists from different fields: dentist, urologist, ophthalmologist, neurologist, gynecologist, surgeon, otolaryngologist. Currently, in detecting focals, it is known that teeth are primarily examined, then the tonsils and only afterwards, the other organs [10]. Focal diseases of the mouth are classified into:

- **odontal**, at teeth level;
- **periodontal**, at periodontium level.

**Odontal** focal infections develop at dental pulp level encapsulated in the endodontic cavities (pulp chamber and root canals) and the periodontal ones develop at the marginal and apical periodontium level.[63] The cause of this infection is polymicrobial flora confinement at sterile tissue level [64,65], following the local inflammation, which progresses to an abscess formation [65,66]. The incidence of odontal focal diseases with impact on long hospitalization is increasing [67, 68]. Most dental focal diseases have a medium intensity, respond well to the topical treatment associated with surgical one and the appropriate antibiotic therapy [67-70].

## Chapter 3. Uveitis

This chapter presents data on uveitis, its clinical modern classification, laboratory investigations used in its diagnosis, as well as the proper treatment. **Uveitis** represents the inflammation of the structures composing the uveal tract: **the iris, the ciliary body and the choroid** [101,102]. In literature, the term “uveitis” has a broader meaning comprising the intraocular inflammations affecting not only the uvea but the adjacent structures, as well [103]. In terms of location of pathological processes, uvea can be divided into two portions: the anterior portion, which is irrigated by the anterior ciliary arteries and the long posterior ciliary arteries and the posterior part, irrigated by the short posterior ciliary arteries. Vascular anatomical disposition corresponds to the limitation of some inflammatory processes in one of the two territories [104]. The presence of two vascular territories, anteriorly (iridociliary) and posteriorly (at choroid level) explains the possibility of the occurrence of limited inflammation, localized to the first territory (anterior), or at the posterior one. In practice, there are cases when the inflammation can affect both territories, simultaneously or successively [105].

Classification of uveitis and its standardization is very important, being the result of more research centers, quantifying the symptoms and the clinical signs making up the evolutionary clinical picture, as well as the progression and the response to the administered treatment [106,107].

The most used classification was that issued by the International Uveitis Study Group (IUSG), which is based on the anatomical localization of inflammation [108]. Panuveitis is also described, a term used to describe the inflammation at the level of several structures: the anterior chamber, vitreous, retina, choroid [108].

In 2005, the Standardization of Uveitis Nomenclature (SUN) Working Group standardized the methods for reporting clinical data (diagnostic terminology, inflammation grading schema, and outcome measures) for uveitis. There was consensus by the group members that the anatomical classification of uveitis based on criteria defined by the International Uveitis Study Group (IUSG) should be used. A standardized grading schema for aspects of intraocular inflammation, that is, anterior chamber cells, anterior chamber flare, and vitreous haze, was developed [109] Standardized definitions of outcomes, including reporting visual acuity outcomes, were approved [110]

In 2008, the International Uveitis Study Group (IUSG) designed a simplified, clinical classification system for uveitis based on etiological criteria. It has, therefore, three main categories, as follows: infectious (e.g. bacterial, viral, fungal, parasitic), noninfectious (e.g. known systemic associations, no known systemic associations), and masquerade (e.g. neoplastic, nonneoplastic) [111]

The Standardization of Uveitis Nomenclature (SUN) Working Group met in 2009 to standardize the descriptions and terminologies necessary to develop tools such as computerized data entry forms and classification criteria. Initial terminology was developed via Web-based surveys, broadband Delphi techniques, and teleconferences. This terminology was then revised by workshop participants using nominal group techniques and supermajority voting. A total of 193 terms were identified and mapped to 28 major uveitic disease entities [112,113]

**Treatment principles** are [131, 118]:

- *Prevention of visual complications*
- *Improvement of the quality of life by reducing discomfort, pain, photophobia*
- *The extent and location of the inflammatory process*
- *Aetiology treatment [132]*



# **SPECIAL PART**

## **Chapter 4. Motivating for the choice of the theme**

The management of anterior uveitis is a frequently addressed issue in ophthalmology and the decision regarding maximal treatment is difficult. The general clinical examination is very important, in conjunction with specialty exams: dental examination, ENT, urogenital, dermatological and internal diseases exams, aiming at detecting a focal infection and at establishing causality so that, the efficiency of the treatment applied to be maximal and the rate of recurrence to be minimized.

A real focal disease is not represented by an acute infectious process; on the contrary, it is represented by an apparently faded infection, in which the microbes are being put into circulation under the form of bursts of germs of attenuated virulence, microbial toxins microbial degradation products, fulfilling the role of antigens. They will release the uveal process with immunological mechanism. Such behaviour is characteristic for dental granulomas, cryptic tonsillitis, hypertrophic chronic sinusitis [116]. The microbial agents involved in triggering the uveal processes are primarily the BK and streptococcus, then, gonorrhoea, pneumococci, pseudomonas, bacillus Coli, staphylococcus and the pneumonia group. Classification and standardization of uveitis is the result of multicenter research, quantifying the symptoms and the clinical signs making up the evolutionary clinical picture, as well as progression and response to the administered treatment [106 107].

## **Chapter 5. Purpose of the paper**

The study of this work deepens the issue of the involvement of the etiology of the focal disease in the etiology of anterior uveitis. To do this, we followed the evolution of the patients hospitalized in the Department of Ophthalmology within the Clinical County Emergency Hospital of Sibiu, between 2008 and 2014, with a diagnosis of anterior uveitis; cases were investigated before and after the removal of any focal diseases. Detecting the etiology of uveitis is difficult under the current conditions, too. However, in those where the cause could be determined, dental focal diseases play an important role. Confirmation of the involvement of dental focals was also made by the therapeutic test, with a favourable evolution after removing the focals. In order to see which types of focal infections are more frequent in anterior uveitis, each patient was submitted to a detailed dental examination, thus establishing the degree of pathogenicity of each dental focal disease in the etiology of uveitis.

For the therapeutic success to be as long as possible, it is imperative that, in addition to the immediate symptomatic treatment, to perform dental examination with the possible removal of the detected dental infections, possible triggers of anterior uveitis.

## Chapter 6. Materials and methods

The study was conducted on 172 patients of both genders, aged between 20 and 90 years old, hospitalized in the Ophthalmology Department within the Clinical County Emergency Hospital of Sibiu, in the period 2008-2014 with a diagnosis of anterior uveitis, patients who had multiple odonto-periodontal lesions. In this study, we tried to establish an interrelation between the presence of dental focal diseases and anterior uveitis. Data were extracted from hospital observation charts after the specialized clinical examination and interdisciplinary examinations (dental, ENT, rheumatology). To obtain a homogeneous sample of patients, we determined the inclusion and exclusion criteria.

### **Inclusions criteria** of the patients:

- Period: 2008-2014;
- Presence of anterior uveitis;
- Possibility of follow-up;
- Informed and agreed consent of the patient or family.

### **Exclusion criteria:**

- Refusal to participate in the trial.

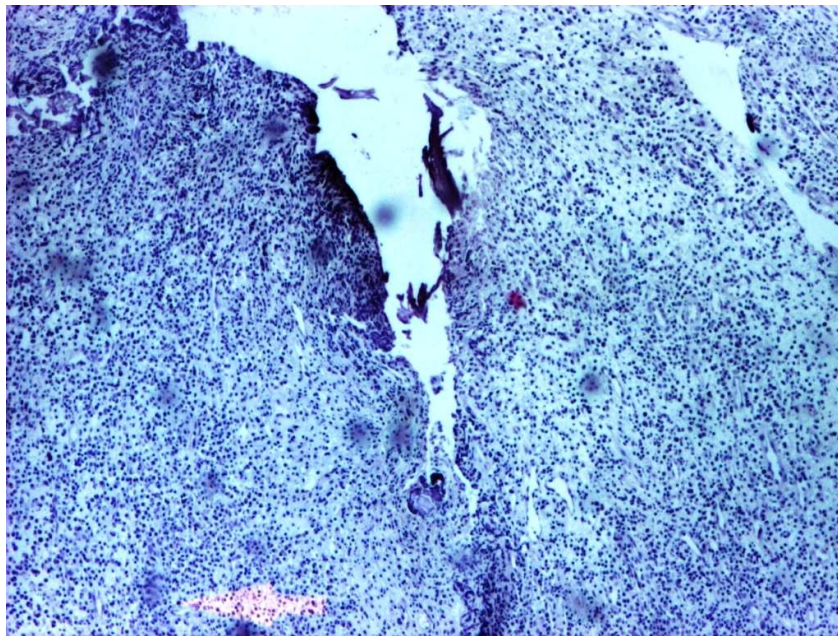To test the hypothesis and the relation of causality between anterior uveitis and the presence of dental focal disease, as well as in order to achieve the aimed objectives, the following **methods** were used:

- ✚ Systematic observation;
- ✚ Performing dental examination to detect the presence of dental focal diseases;
- ✚ Histopathological analysis of the resulted biological material;
- ✚ Case study;

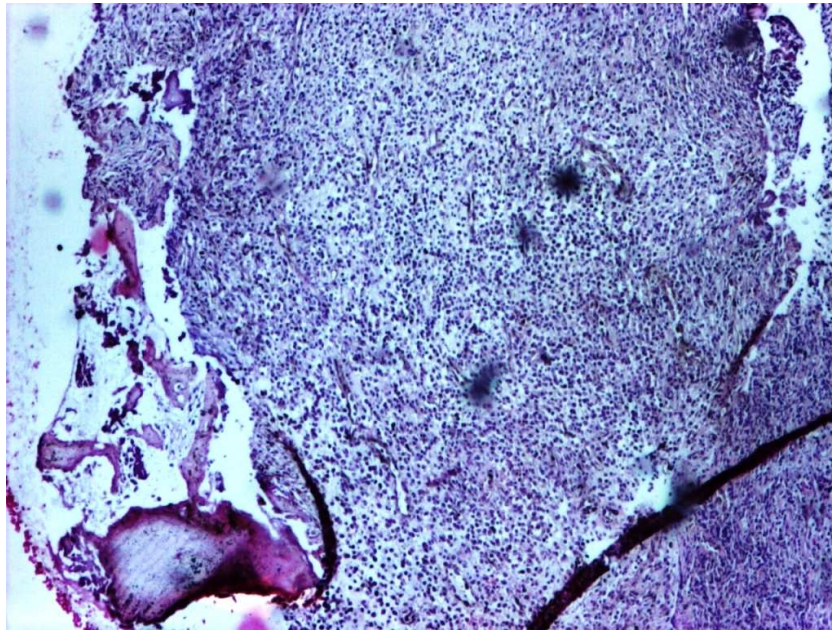
📄 Documents analysis;

📄 Statistical analysis of the data.

The microscopic aspect of the biological product resulting after the applied dental treatment can be described as follows: at dental root level, all around the apex, in contact with the apex, there can be noticed a well-delimited formation, reddish, of soft consistency, having the size of a grain of pepper. Microscopically, after the magnification examination of 40x, 100x, 200x, 400x, there can be described a nodular formation, made up of lax connective tissue, containing blood capillaries and numerous cells: lymphocytes, plasma cells, histiocytes, fibroblasts, PMNs; more round cells appear with clear cytoplasm, foamy, small, hyperchromic nucleus (lipophages) (figure no. 1). Outside the formation, there stands a denser conjunctive tissue, forming a fibrous capsule. In recent granulomas' structure, PMN cells prevail, numerous neofunction capillaries in a looser stroma (figure no. 2). While phenomena of fibrosis are installed, capillaries decrease numerically, occurring fibroblast cells in evolution, old lymphoplasmocytes and stroma becomes fibrous. Thus, the diagnosis takes into account the presence of non-specific granulation tissue located around the root apex (lipophage cells appearing after phagocytosis of fats derived from alveolar bone destruction).



**Figure no. 1 Histopathological aspect of the biological product (personal collection)**



**Figure no. 2 Histopathological aspect of the biological product (personal collection)**

## **Chapter 7 Results interpretation**

Statistical processing was performed using SPSS v16 software. Statistical Package for the Social Sciences is one of the most used software in data statistical analysis. To perform the statistical analysis in this research, the following were used:

- ***comparing two qualitative variables table of associations (Crosstabs).*** The significance level (p) of the Likelihood ratio test was taken into consideration. Interpretation of the degree of association between variables is as follows:
  - if  $p \leq 0,01$  means that **the variables are significantly associated** (with an accuracy of 99%).
  - if  $p \leq 0,05$  means that **the variables are significantly associated** (with an accuracy of 95%).
  - if  $p > 0,05$  means that **the variables are not significantly associated**.
- ***Comparing the means of the variants of a qualitative variable (Compare Means).***

Tests were performed on means and proportions to check if there are significant differences between them. A significance level of  $p \leq 0.05$  points out that the

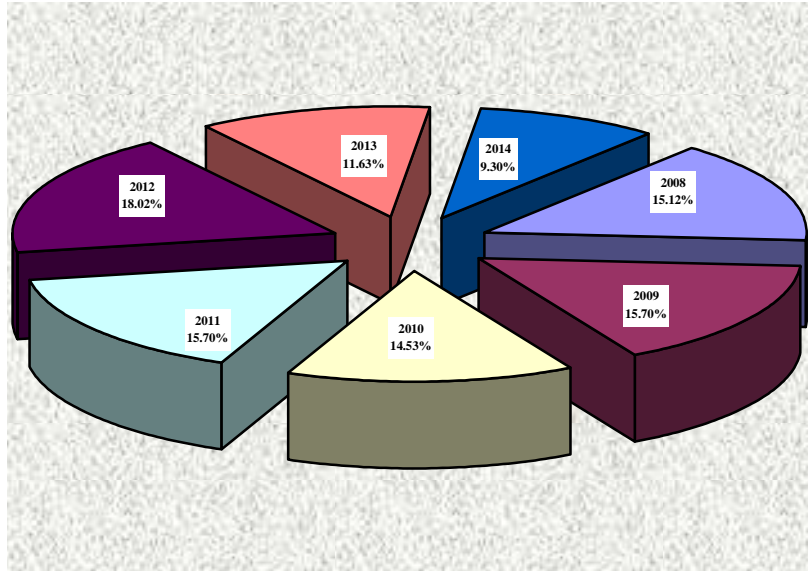
hypothesis of equality of the means per group is rejected, so we can say that variable variants differ significantly.

As one can notice (see table no. 1), there were included in the study a total of 172 patients with a diagnosis of anterior uveitis, hospitalized in the Ophthalmology Department within the County Clinical Emergency Hospital of Sibiu, over a period between 2008 and 2014. The study patients had different backgrounds, both urban and rural, the data showing a predominance of those from urban areas. In terms of gender, there were studied 172 patients, both females, 84, and males, 88 patients, observing that the ratio between the two genders is almost equal, both in general and in terms of distribution, regarding the area of origin.

**Table no. 1. Distribution of the study group per years**

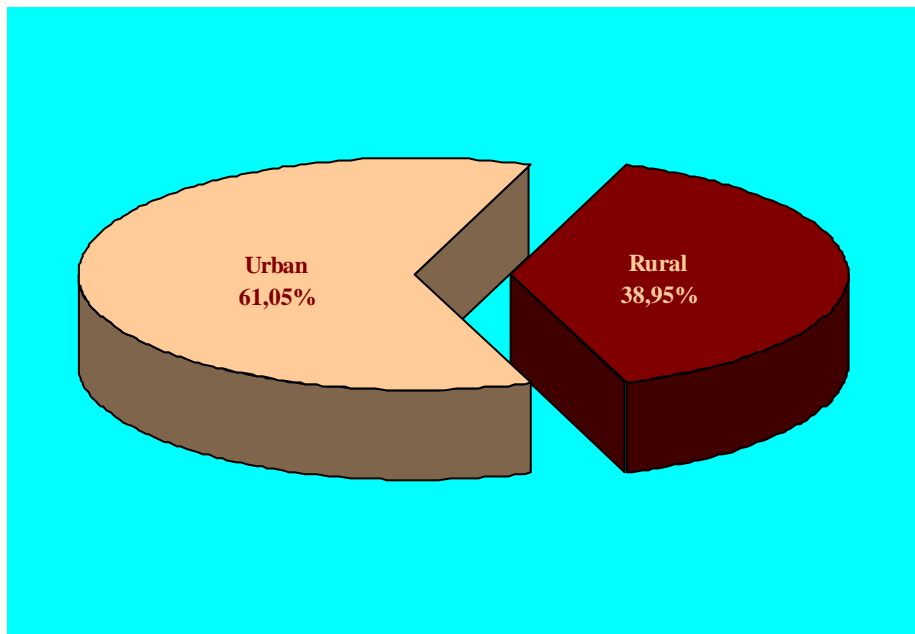
Year	Urban			Rural			Total		
	Male	Female	Total	Male	Female	Total	Male	Female	Total
<b>2008</b>	5	5	10	7	9	16	12	14	<b>26</b>
<b>2009</b>	11	8	19	4	4	8	15	12	<b>27</b>
<b>2010</b>	7	13	20	5	0	5	12	13	<b>25</b>
<b>2011</b>	5	12	17	6	4	10	11	16	<b>27</b>
<b>2012</b>	14	6	20	5	6	11	19	12	<b>31</b>
<b>2013</b>	4	5	9	7	4	11	11	9	<b>20</b>
<b>2014</b>	4	6	10	4	2	6	8	8	<b>16</b>
<b>Total</b>	<b>50</b>	<b>55</b>	<b>105</b>	<b>38</b>	<b>29</b>	<b>67</b>	<b>88</b>	<b>84</b>	<b>172</b>

Regarding the annual predominance, there could be noticed a maximum of 18,02%, for the year 2012, with a minimum incidence in 2014 of 9,30% (figure no. 3).



**Figure no. 3 Distribution of the study group per years**

The area of origin is a relative factor in the etiology of anterior uveitis, the examined patients registering urban origin predominance (figure no. 4).



**Figure no. 4. Study group distribution according to area of origin**

In terms of uveitis location in relation to the patients' age, it was found that the greatest damage was in the age group between 31-50 years old, and the location of the anterior uveitis prevailed in the right eye (49.4%) (table no. 2).

**Table no. 2. Uveitis location according to age group**

Age group	Uveitis location			Total	P test Likelihood ratio
	Both eyes	Right eye	Left eye		
≤30	<b>1</b>	<b>7</b>	<b>8</b>	<b>16</b>	<b>0,001</b>
	6.3%	43.8%	50.0%	100.0%	
31÷50	<b>6</b>	<b>30</b>	<b>19</b>	<b>55</b>	
	10.9%	54.5%	34.5%	100.0%	
51÷60		<b>19</b>	<b>19</b>	<b>38</b>	
		50.0%	50.0%	100.0%	
61÷70	<b>1</b>	<b>11</b>	<b>26</b>	<b>38</b>	
	2.6%	28.9%	68.4%	100.0%	
>70	<b>3</b>	<b>18</b>	<b>4</b>	<b>25</b>	
	12.0%	72.0%	16.0%	100.0%	
Total	<b>11</b>	<b>85</b>	<b>76</b>	<b>172</b>	
	6.4%	49.4%	44.2%	100.0%	

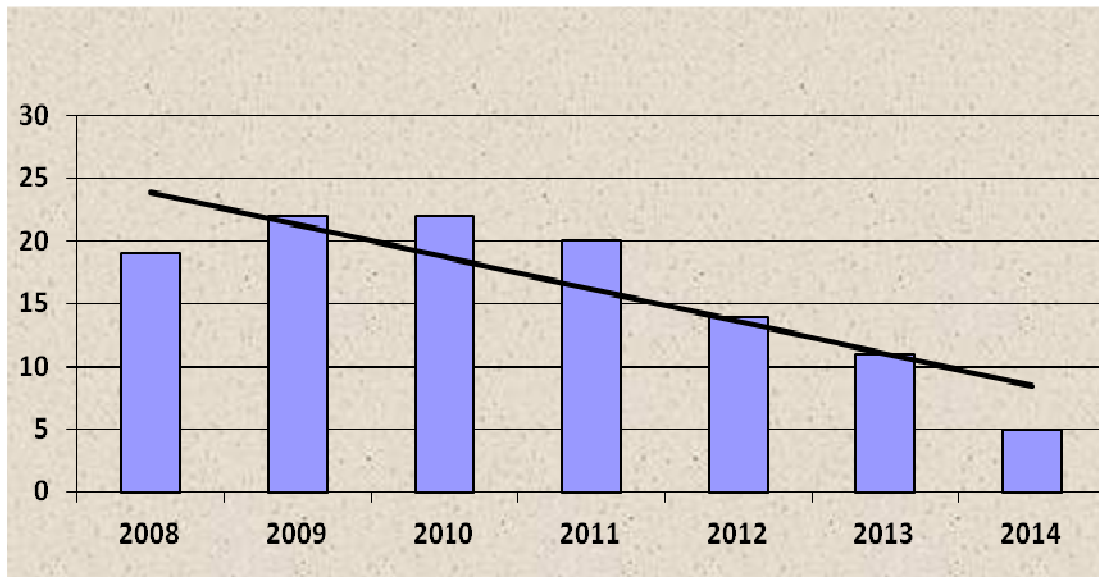
Taking into account the fact that a dental focal infection may be causally related to the pathogenesis of anterior uveitis, in the study group there was followed the frequency of dental examination performance and the associated pathology. Thus, one can say with accuracy of 99% ( $p = 0.000$ ), that there is an association between year and dental examinations, so that in the first 2 years (2008 and 2009), 36.3% of patients did not conduct any dental examination compared to the last two years, when the number of those who were not examined dentally is lower (16 patients, 14.1%), but increasing, in exchange, the rate of those examined and treated dentally (33.9%). Therefore, there was found a low frequency regarding the presence of this examination in 2008 in only 7 patients (11.9%) and only 5 patients in 2009 (8.5%), 3 in 2010 (5.1 %) (table no. 3). Subsequently, there is an increase in the number of patients who have been dentally examined, registering a maximum level in 2012, when a total of 17 patients were examined from this point of view (28.8%). The number of patients with anterior uveitis who were dentally examined was 59 out of a total of 172 study patients.

**Table no. 3. Preponderance of the dental examination in the study patients**

Year	Dental examination		Total	p Likelihood ratio
	yes	no		
2008	7	19	26	0,000**
	11.9%	16.8%	15.1%	
2009	5	22	27	
	8,5%	19.5%	15.7%	
2010	3	22	25	
	5.1%	19.5%	14.5%	
2011	7	20	27	
	11.9%	17.7%	15.7%	
2012	17	14	31	
	28.8%	12.4%	18.0%	
2013	9	11	20	
	15.3%	9.7%	11.6%	
2014	11	5	16	
	18.6%	4.4%	9.3%	
<b>Total</b>	<b>59</b>	<b>113</b>	<b>172</b>	

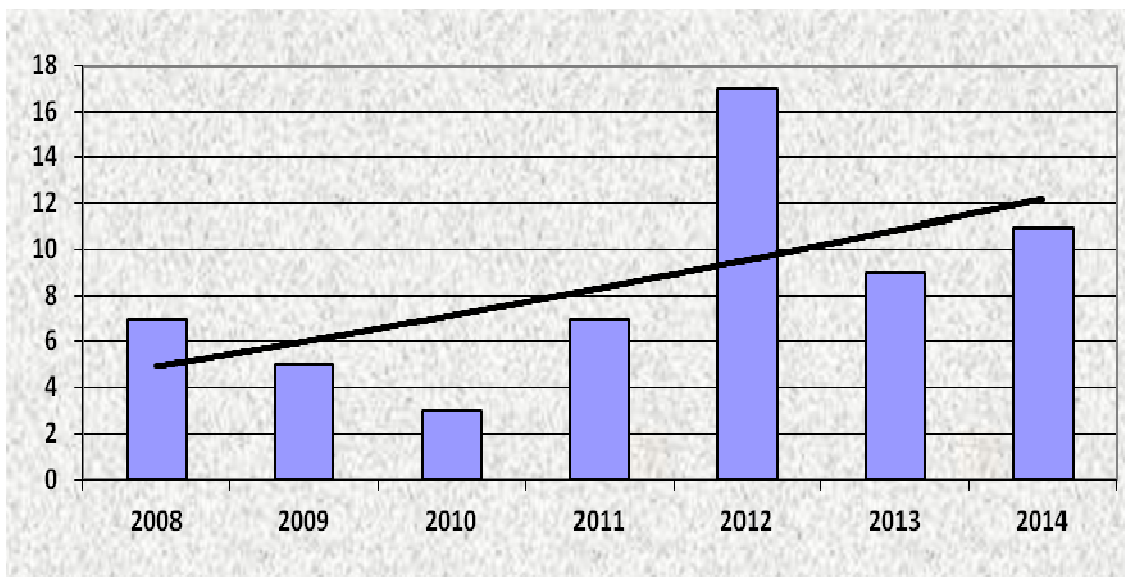
By analysing the data in this study, it was noticed a decrease in the number of patients who were examined in terms of dental focal infections in relation to the studied period of time (figure no. 5).





**Figure no. 5. Year distribution of the group of patients without dental examination**

Also, there is a clear preponderance of a detailed dental examination of the patients (aiming to detect any dental focal infection), especially in the last few years, during which the study was conducted (figure no. 6).



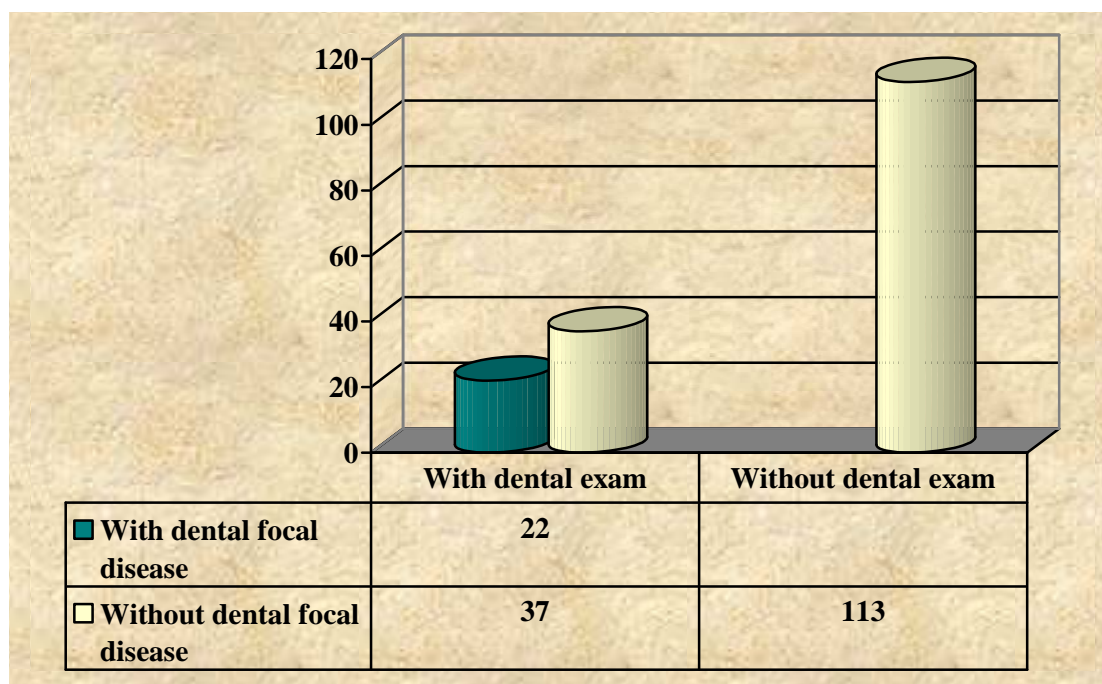
**Figure no. 6. Year distribution of the group of patients with dental examination**

Of the total patients examined over the entire period (2008-2014), in 59 of them dental examination was performed (34.3%). On the occasion of the dental examination performed, dental focal diseases were identified in 22 patients, as demonstrated by the data presented in the table below (table no. 4).

**Table no. 4. Repartition between the frequency of dental examination and presence of focal dental disease**

Dental focal infection present	Dental examination		Total	p Likelihood ratio
	yes	no		
yes	22		22	0,000**
	100.0%		100.0%	
no	37	113	150	
	24.67%	75.33%	100.0%	
Total	59	113	172	
	34.3%	65.7%	100.0%	

In the following figure, we can see very well the proportion of patients with dental investigation conducted but also with the presence of associated dental focal infections (figure no. 7).



**Figure no. 7 Repartition between the frequency of patients with dental exam and the presence of dental focal infection**

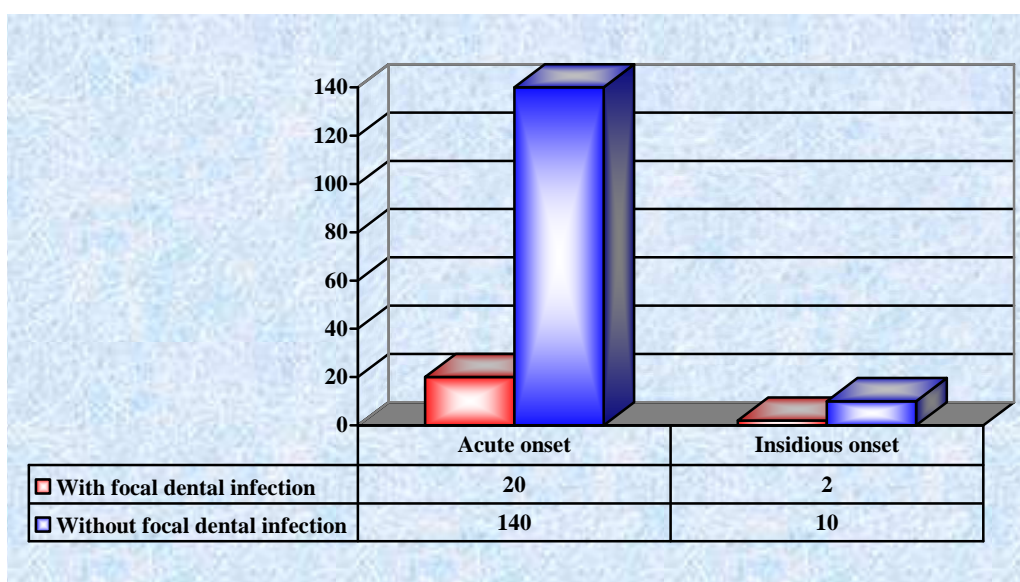
In the study group, it was found out that uveitis onset was acute in 160 patients and insidious in the remaining 12. From the data collected and processed, it was found that in a

percentage of 90.9% of patients with dental focal infection, the disease onset was acute (table no. 5).

**Table no. 5. Dental focal infection and the type of onset in uveitis**

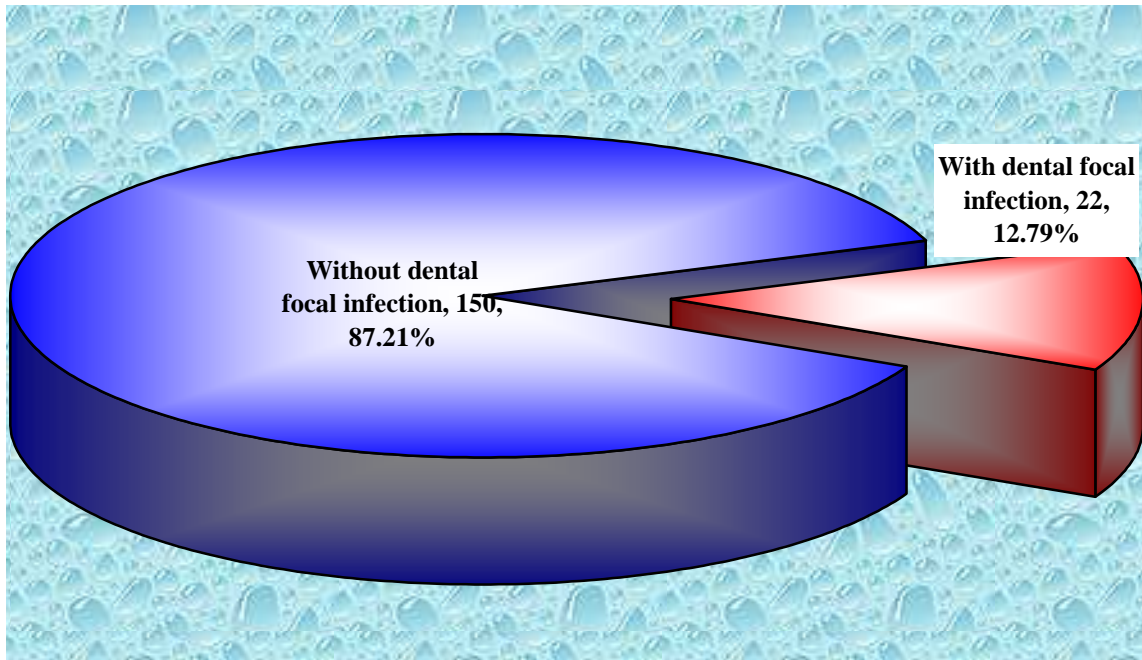
Dental focal disease present	Onset		Total	p Likelihood ratio
	acute	insidious		
yes	<b>20</b>	<b>2</b>	<b>22</b>	<b>0,591</b>
	90.9%	9.1%	100.0%	
no	<b>140</b>	<b>10</b>	<b>150</b>	
	93.33%	6.67%	100.0%	
Total	<b>160</b>	<b>12</b>	<b>172</b>	
	93.02%	6.98%	100.0%	

The onset in the patients with dental focal infection identified upon the dental examination was acute in a number of 20 patients, compared to only 2 patients with insidious onset, the proportion remaining positive for acute onset and for patients who have not had detectable dental focal diseases, 140 patients (figure no. 8).



**Figure no. 8. Type of onset according to the presence of focal dental disease**

Of patients with dental exam performed, 22 had dental focal infections (12.79%) (figure no. 9), and in 10 patients, it was possible to perform histopathological examination of the biological product resulting from the dental treatment applied.



**Figure no. 9. Relation of patients with dental focal infection present**

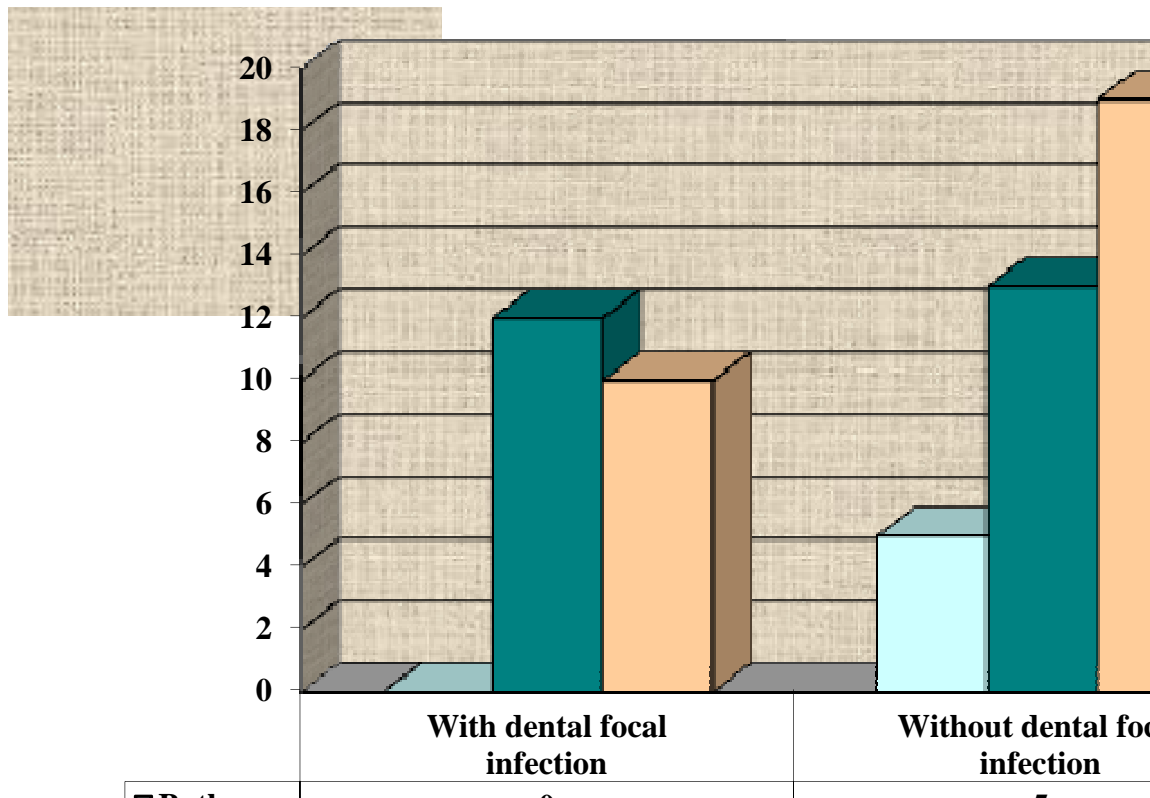
The analysis of biological product resulting from the dental treatment applied in patients with dental focal infections detected after the dental examination, revealed a nodular formation composed of lax connective tissue, which contains blood capillaries and numerous cells, such as: lymphocytes, plasma cells, histiocytes, fibroblasts, PMN or there appear large round cells with clear cytoplasm, foamy with small, hyperchromic nucleus (lipophage cells). Outside the formation, there stands a denser connective tissue, forming a fibrous capsule. In recent granulomas' structure, PMN cells prevail, numerous neo-formation capillaries with a looser stroma. Thus, there was noticed an increased presence of PMNs (55.6%) or relative (44.4%) in the patients who experienced an acute onset, in terms of dental focal infection (9 patients). Also, a similar presence was noticed in the presence of lymphocytes.

Following the histopathological analysis of the biological product resulted from the dental treatment applied, it was found that the onset was acute in 9 patients versus 1 insidious onset, in one single patient (table no. 6). This result was obtained by analyzing the presence or absence of the elements characteristic of dental granuloma, whose data were presented in the above tables.

**Table no. 6. Type of clinical onset according to the histopathological characteristics**

Histopathological result	Clinical onset		Total	p test Likelihood ratio
	Acute	Insidious		
<b>Acute</b>	<b>5</b>		<b>5</b>	<b>0,221</b>
	100.0%		100.0%	
<b>Chronic</b>	<b>4</b>	<b>1</b>	<b>5</b>	
	80.0%	20.0%	100.0%	
<b>Total</b>	<b>9</b>	<b>1</b>	<b>10</b>	
	90.0%	10.0%	100.0%	

Compared to those 59 patients with diagnosed uveitis, but also with a dental examination performed during hospitalization, it may be said that the location of the uveal process was approximately equal in both eyes in relation to the presence of dental focal disease simultaneously detected and treated (figure no. 10).

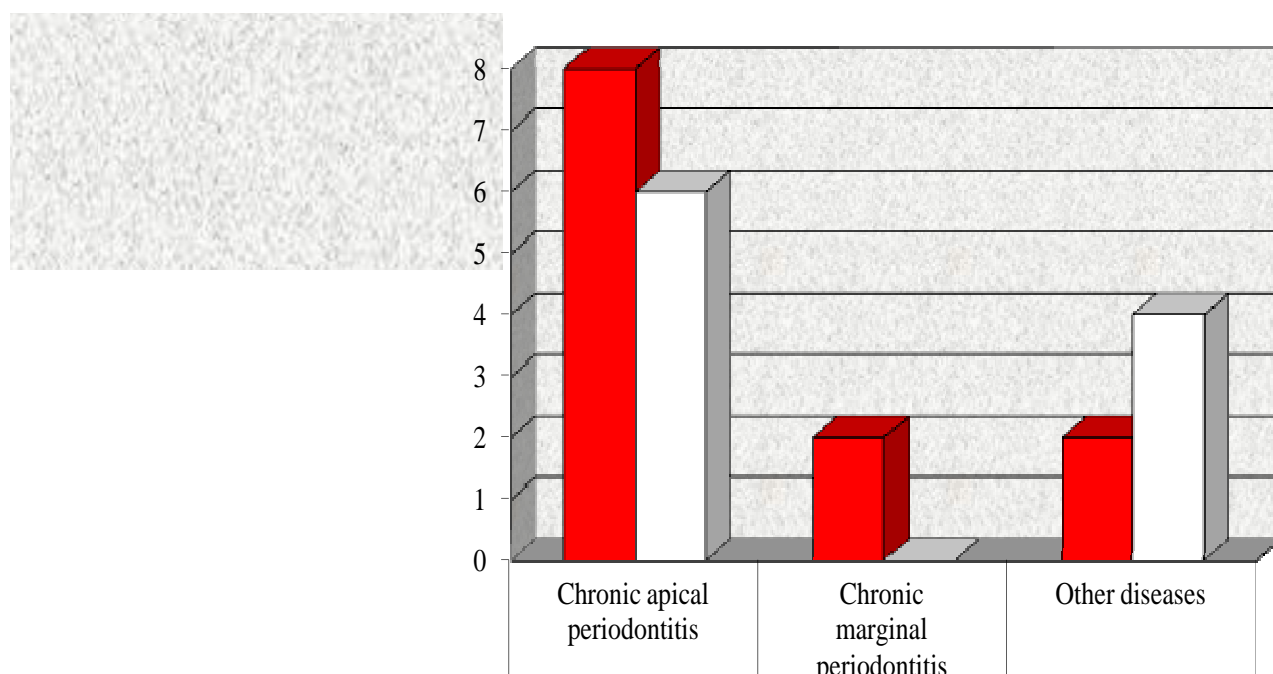


**Figure no. 10. Repartition of uveitis location according to the existence of dental focal disease**

Following the dental examination conducted in 59 patients with symptomatic uveitis, in those 22 patients with dental focal infection, there were detected granulomatous chronic apical periodontitis in 14 patients, chronic marginal periodontitis in 2 patients, other diseases in 6 patients (table no. 7 figure no. 11).

**Table no. 7. Repartition of uveitis location according to diagnosis**

Diagnostic	Uveitis location			p Test Likelihood ratio
	Right eye	Left eye	Total	
Chronic apical periodontitis	<b>8</b>	<b>6</b>	<b>14</b>	<b>0,169</b>
	66,7%	60,0%	63,6%	
Chronic marginal periodontitis	<b>2</b>	<b>0</b>	<b>2</b>	
	16,7%	,0%	9,1%	
Other diseases	<b>2</b>	<b>4</b>	<b>6</b>	
	16,7%	40,0%	27,3%	
<b>Total</b>	<b>12</b>	<b>10</b>	<b>22</b>	



**Figure no. 11. Repartition of uveitis location according to diagnosis**

## **Chapter 8. Case studies**

This chapter takes into consideration and presents eloquent cases, way of diagnosis and treatment of uveitis, as well as the dental treatment simultaneously applied, the imaging techniques accompanying all presentations being at the same time suggestive and characteristic. The novelty of the thesis is represented by the histopathological examination of the biological product resulted following the dental treatment applied. This examination has confirmed the nature of the infectious process, decisively contributing to correctly applying the treatment with a view to obtain a favourable evolution of the patient.

## **Chapter 9. Discussions**

Focal infections are equally isolated processes, apparently faded, where the microbes are encapsulated and from where, there are released into circulation, germs with attenuated virulence, microbial toxins, microbial degradation products, with antigen role that will trigger the uveal process with mechanism, therefore immunological.

Such behaviour is characteristic of dental granulomas, cryptic tonsils, hypertrophic chronic sinusitis [116]. Odontal focal diseases have as the developing point the dental pulp, being located in the endodontic cavities (pulp chamber, root canals), while the periodontal ones are developing in the marginal or apical periodontium [63].

The cause of this infection is polymicrobial flora confinement in the sterile tissue [64,65], following by local inflammation and progression to an abscess formation [65,66]. The incidence of odontogenic focal infections with increased impact on the duration of hospitalization is increasing [67, 68].

Most of the dental focals have medium intensity, respond well to the local treatment associated with surgery and appropriate antibiotic therapy [67-70]. In this study, there were examined 172 patients with a diagnosis of anterior uveitis, hospitalized in the Ophthalmology Department within the Clinical County Emergency Hospital of Sibiu, between 2008 and 2014.

From the point of view of the number of cases studied and reported per year, there can be noticed an approximate proportion in terms of years. The study patients were coming from different backgrounds, both urban and rural, the data showing a predominance of those from urban areas. In terms of gender, there were studied 172 patients, both females, 84, and males, 88, noticing that that the ratio between the two genders is almost equal, both in general, and in terms of repartition in relation to the origin environment.

Regarding the annual predominance, there could be noticed a maximum of 18,02%, for the year 2012, with a minimum incidence in 2014 of 9,30%, but in terms of the distribution per year and area of origin, we can say with an accuracy of 95% ( $p = 0.045$ ), that there is an association between year and area of origin, so that in 2008, the studied pathology was predominant in rural areas (61.5%) compared with 2010, when in urban areas, there were 80% of cases. One cannot say that there is an association between the patient's condition and the environment of origin ( $p = 0.070$ ), but it can be observed that the acute onset is predominantly in patients from rural areas. The area of origin is a relative factor in the etiology of anterior uveitis, the examined patients registering urban origin predominance, while as for the distribution by gender, it was found that the pathology is more frequent in the male gender (51.16%) compared to a lower percentage in female gender (48.84%), but with a trend of slight predominance in urban areas of the female gender and inversely, male gender predominance in the patients coming from rural areas

In terms of uveitis location in relation to the patients' age, it was found that the greatest impairment was in the age group between 31-50 years old, and the location of the anterior uveitis prevailed in the right eye (49.4%).

Taking into account the fact that a dental focal infection may be causally related to the pathogenesis of anterior uveitis, in the study group there was followed the frequency of dental examination performance and the associated pathology. Thus, one can say with accuracy of 99% ( $p = 0.000$ ) that there is an association between year and dental examinations, so that in the first 2 years (2008 and 2009), 36.3% of patients did not conduct any dental examination compared to the last two years, when the number of those who were not examined dentally is lower (16 patients, 14.1%), but increasing, in exchange, the rate of those examined and treated dentally (33.9%). Therefore, there was found a low frequency regarding the presence of this examination in 2008 in only 7 patients (11.9%) and only 5 patients in 2009 (8.5%), 3 in 2010 (5.1 %) (table no. 3). Subsequently, there is an increase in the number of patients who have been dentally examined, registering a maximum level in 2012, when a total of 17 patients were examined from this point of view (28.8%). The number of patients with anterior uveitis who were dentally examined was 59 out of a total of 172 study patients. Regarding the dental examination performed, there is a clear preponderance of a detailed dental examination of the patients (aiming to detect any dental focal infection), especially in the last few years, during which the study was conducted. In terms of associated pathology, in relation to the dental examination carried out in the study patients, it was found an association with inflammatory



diseases in a number of 23 patients out of 54. It was also found that a number of 2 patients presented other ocular associated diseases and an absence rate of 36.2% of the associated pathology. One cannot say that there is an association between dental exam and associated diseases ( $p = 0.152$ ), but in 49.2% of those who underwent dental examination, there were found associated inflammatory diseases. From the point of view of the onset of the disease, in 172 patients enrolled in the study for the entire period, it was found that the onset of the eye condition was acute in 160 patients, predominantly compared to a chronic onset of ocular symptomatology in 12 patients. Of all examined subjects, it was found a predominantly acute onset in the patients who have also been dentally examined in order to detect an associated dental focal disease. Therefore, it was found that in 113 patients in whom dental examination could not be performed, uveal ocular symptoms onset was predominantly acute in a percentage of 95.76% (108 patients) compared with an insidious onset in only 5 patients (4.24%). One cannot say that there is an association between the type of onset and the performance of dental examination ( $p = 0.070$ ). During patients' examination, the association of inflammatory or other diseases was also aimed at, with the studied ocular pathology and also with the presence of dental focal infections. Thus, in the group of patients who experienced dental examination, other associated diseases were also found, such as: sinusitis with various sites (maxillary and frontal), as well as rheumatic inflammatory diseases (rheumatoid arthritis, ankylosing spondylitis, Felty's syndrome, Reiter's syndrome). It was noted the possibility of associating inflammatory sinus diseases with inflammatory rheumatic diseases, but also with other systemic or ocular diseases. Out of the 73 patients with associated pathology, 29 were examined in terms of dentistry.

We can say with 99% accuracy, that there is an association between performing dental examination and inflammatory diseases ( $p = 0.006$ ), so of those with dental exam, 48.3% had ankylosing spondylitis and 17.2% maxillary sinusitis. Following the study carried out for the entire group of patients with uveal symptoms, it was found that other ocular pathologies can be associated that may overlap the uveal predominant symptoms. Therefore, the presence of corneal ulcer was found in 1 patient, the presence of pupillary membrane in 1 patient as well, and one patient had secondary glaucoma or association with kerato-conjunctivitis. Secondary glaucoma association with diabetes, hypertension was also found in 4 patients. Other associated ophthalmic diseases were senile cataracts, corneal ulcer or herpetic keratitis. In the study group, it was found that uveal disease onset was acute in a number of 160 patients and insidious in the remaining 12. From the data collected and processed, it was found that a

percentage of 90.9% of patients with dental focal infection, the onset was acute. Of the total patients examined during the entire period 2008-2014, in 59 of them dental examination was performed (34.3%). Of the patients who had performed dental exam, 22 presented dental focal infections (12.79%), and in 10 patients, there could not have been performed the histopathological examination of the biological product resulting from the dental treatment applied.

Compared to those 59 patients with diagnosed uveitis, but also with a dental examination performed during hospitalization, it may be said that the location of the uveal process was approximately equal in both eyes in relation to the presence of dental focal disease simultaneously detected and treated (figure no. 10). It cannot be said that there is an association between dental focal infection and uveitis location ( $p = 0.051$  - Likelihood ratio test). It may be observed, however, that of those with dental focal disease, in 54.5% of the cases uveitis location is in the right eye.

Compared to the acute onset of uveal symptoms, in relation to the presence of dental focal disease and monitoring visual acuity between the time of admission and that of discharge, the chronic onset is noticed, which is directly related to the steady evolution of visual acuity and a favourable evolution of patients in whom onset was acute. Data were examined for symptoms detected in the right eye, both upon admission and at discharge.

Therefore, compared to the right eye, the difference in visual acuity between the time of admission and that of discharge is steady in a number of 2 patients with acute onset and 4 patients with chronic course. The favourable evolution was found in 3 patients who experienced acute onset and only one patient had a chronic course. Of a total of 10 patients, all had acute onset and chronic course, regarding the right eye, in general, there was a slight predominance in the patients with mild evolution (6 patients), compared to only 4 patients with favourable evolution. One cannot say that there is an association between the condition of the patient and the difference in visual acuity ( $p = 0.189$ ). The study of uveal symptoms in relation to the presence of focal dental disease and acute or chronic onset, correlated to the evolution of the vision acuity in the left eye showed an approximately equal value between the acute and chronic onset. Following the dental examination performed in the 59 patients with uveal symptoms, in those 22 with focal dental disease, there was detected chronic apical periodontitis in a total of 14 patients, 2 patients had chronic marginal periodontitis and other diseases were identified in 6 patients. One cannot say that there is an association between

uveitis location and dental focal disease location ( $p = 0,224$ - Likelihood Ratio Test), but it can be noticed that the location of uveitis in the left eye is 50% for the dental focal infection at jaw level. It cannot be said that there is an association between uveitis location and location of dental focal infection according to the damaged side ( $p = 0,224$ - Likelihood Ratio Test), but it can be seen that the location of uveitis in the left eye is 40% for the dental focal infection, both on the right and left side.

In terms of uveal inflammatory process location related to the affected teeth, left laterally, it was found that there were 12 cases of uveitis location in the right eye and in 10 cases, the inflammatory process was ipsilaterally to the dental focal infection. In terms of localization of uveitis, lateralized to the left or right eye, in relation to the location of the dental focal infection (at frontal or lateral teeth), it was found that there is no association ( $p$  likelihood ratio 0.949), but there was noticed a determination of uveitis located in the right eye by the dental focal infections localized on the right side. One cannot say that there is an association between dental focal disease and patient's status on discharge status ( $p = 0.362$  - Likelihood ratio test). It can be said that of those with dental focal infections, 59.1% had an improved evolution on discharge.

It was found that in a number of 22 patients, respectively those with dental focal infections detected on dental exam, the average length of stay was of 7.18 days, compared with an average of 8.22 days of hospitalization in those with dental exam but without dental focal disease or other associated dental pathology. Average days of hospitalization in the entire group of patients with dental exam was of 7.83, so it cannot be said that there is a statistically significant difference between the average days of hospitalization and the existence of dental focal infection ( $p = 0.310$ ). In terms of the treatment administered to those 59 patients examined, both ophthalmologically and dentally, it was found that all received general and local treatment. Regarding the 22 patients with dental focal infection, it was found that most of them received antibiotics in most cases in combination with anti-inflammatory, mydriatic and ocular hypotensor drugs. In terms of local treatment given to patients with dental focal infections, it was noticed that the majority received a local mydriatic drug most often in combination with an AIS, NSAIDs, antibiotic or ocular hypotensive agent. Regarding the general treatment administered, it was found that all patients with dental focal infection received treatment, and among the administered agents, the group of antibiotics in combination with AIS or NSAID and pain relievers were predominantly administered. In terms of location of the uveal inflammatory process, it was found that it affected both eyes in

a number of 11 patients, with a greater involvement in the right eye (85 patients), compared to 76 patients with damage in the left eye. From the point of view of visual acuity, it was observed that it was normal in 22 patients with uveitis location in the right eye, but it was low in most patients with damaged right eye (74.1%).

We can say with a certainty of 99% ( $p = 0.000$  - Likelihood ratio test) that location of uveitis depends on both the level of visual acuity in the right eye and in left eye. In terms of uveitis location in the left eye, it was found upon hospitalization that visual acuity was normal in a number of 18 patients, while in a higher percentage of 76.3%, there was found decreased visual acuity at the level of the left eye (table no. 43). From the point of view of both eyes damage, there have been a number of 11 patients who had changes in the visual acuity following uveitis location in both eyes.

Evolution of visual acuity was aimed at during hospitalization and according to the location of uveitis, so that after collecting and statistically analyzing the data, one can say with accuracy of 99% ( $p = 0.000$  - test Likelihood Ratio) that the level of visual acuity at discharge is improved compared with the visual acuity level upon admission, taking into account uveitis location, and this is mostly due to the administered treatment. Thus, of 172 patients in the study group, 49 with uveitis location in the right eye showed an improvement of the visual acuity, while 34 patients showed a steady evolution of visual acuity on discharge and a small percentage of 2.4% showed worsening of visual acuity at discharge (patients with uveal process location in the right eye).

Data from the survey were collated and aimed at the correlation between visual acuity in the eye right, from the time of admission and discharge of patients, related to the number of days of hospitalization. It was found that during hospitalization, patients experienced several evolutionary paths, prevailing the favourable evolution in 64 patients, most of them having a steady evolution (106 patients). There was also a negative evolution, regarding symptoms worsening in 2 patients. Related to the number of days of hospitalization, it was noticed that the length of stay was longer in the patients with favourable evolution. Data on the evolution of visual acuity in the left eye, between the time of admission and at discharge, also showed a predominance of a steady evolution (89 patients) in the study group, compared to 83 patients with favourable evolution.

The average days of hospitalization in the patients with favourable evolution during hospitalization was of 7.83 days, compared with 9.18 days in those with favourable outcome

(table no. 44). It was also found that for the patient to present a favourable evolution, there is need for a greater number of days of hospitalization. In conclusion, we can say with a certainty of 95% ( $p = 0.036$  for the right eye,  $p = 0.07$  for the left eye), that there is a significant statistical difference between the number of days of hospitalization and visual acuity difference. Improving visual acuity difference requires a greater number of days of hospitalization. From the point of view of the patient's health status at discharge, there was noticed a healing evolution in 64 patients, who required an average length of hospitalization of approximately 9.55 days. The number of patients discharged in improved condition prevailed - 99 patients, but the average length of stay was of 7.95 days, compared with 9 patients who were discharged in a steady condition but whose average length of stay was of 6.78 days. There is therefore the need for a greater length of hospital stay in order to obtain the recovery of patients. In terms of the treatment administered to the study group, it was found that patients received drug combinations that included antibiotics, ocular hypotensive drugs, mydriatic agents, pain relievers, vitamins in different combinations adapted to each case. One cannot say that there is an association between uveitis location and the type of treatment ( $p = 0,455$ - Likelihood ratio test). Noteworthy is that all patients received non-steroidal and anti-inflammatory steroids locally and / or generally administered.

## **Chapter 10. Conclusions**

1. The purpose of the investigation focused on the study of anterior uveitis and on the importance of accurate detection and treatment of dental focal disease by identifying through histopathological examination, the biological product resulting after dental treatment.
2. Research hypotheses were:
  - The correct diagnosis of patients with anterior uveitis, by clinical examination and laboratory tests allow to apply the appropriate treatment.
  - Identification of patients with dental focal infection, through a thorough dental examination, and confirmed by histopathological examination of the biological product resulting after the applied treatment.
3. Objectives of the investigation consisted in:
  - Establishing an accurate clinical and paraclinical diagnosis of the anterior uveitis;
  - Identifying dental focal diseases;

- Identifying the etiology of the dental focal diseases, for the treatment of anterior uveitis to be complete, and for the rapid socio-professional reinsertion of the patient.
4. The study was conducted in the Ophthalmology Department within Sibiu County Clinical Emergency Hospital, between 2008 and 2014. There were investigated a total of 172 patients. In terms of annual predominance, a maximum of 18.02% was noticed in the year 2012, with a minimum incidence in 2014, the percentage being of 9.30%.
  5. The area of origin is a relative factor in the etiology of anterior uveitis, most of the examined patients were coming from urban areas. Anterior uveitis incidence is higher in urban areas (61.05%), stress being a well-known factor in triggering and maintaining uveal disease.
  6. In terms of distribution by gender, it was found that the pathology is more frequent in the male gender (51.16%) compared with a lower number in the female gender (48.84%), but with a slight predominance of females in urban areas and of males in rural areas.
  7. The study included patients aged 20-90 years old, the greatest damage was in the age group between 31-50 years old with a total of 55 patients.
  8. Etiology of anterior uveitis is difficult to set even under the current conditions; a possible etiology being defined only in a small number of cases.
  9. In terms of uveitis location related to the age of the examined patients, it was found that the greatest impairment was in the age group of 31-50 years old, and the location of the anterior uveitis prevailed in the right eye (49.4%) and 70 years old (72% right eye), but at a rate approximately equal in other age groups.
  10. To study the etiology of anterior uveitis, dental examination is indicated; in this research, 59 patients could be dentally examined of the total of 172 patients included in the study.
  11. From the point of view of the associated pathology, in relation to carrying out dental examination in the patients included in the study, there was noticed the association of inflammatory diseases in 23 patients.
  12. The onset of uveal pathology was predominantly acute in 160 patients. Therefore, it was found in a total of 113 patients who could not be dentally examined, that uveal ocular symptoms onset was predominantly acute in a percentage of 95.76% (108 patients), as compared with an insidious onset in only 5 patients (4.24%).
  13. One cannot say that there is an association between the patient's condition and the area of origin ( $p = 0.070$ ), but it can be observed that acute onset is predominantly in rural patients.

14. In terms of associated pathology, it was found that 73 patients had other associated diseases of which, an important part was played by inflammatory diseases at the level of facial sinuses (maxillary sinusitis), but also by systemic rheumatic diseases (rheumatoid arthritis, ankylosing spondylitis).
15. The clinical onset of uveitis symptoms may overlap a pre-existing eye condition. Thus, in 26 patients coexisted associated eye diseases.
16. Diabetes and associated heart diseases were the most common associated general pathology.
17. Of patients who were dentally examined respectively 59, 22 patients experienced odonto-periodontal focal diseases (12.79%).
18. Uveitis location in relation to the dental focal disease was in 54,5% in the right eye and in 45,5% in the left eye.
19. Dental focal infections were most commonly located in the jaw, 45.5% versus 31.8% at mandible level, both 22.7%.
20. Dental focal infections were represented by granulomatous chronic apical parodontitis, 63,6%, chronic marginal parodontitis in 9,1% of patients and other conditions – 27,3%.
21. From the point of view of the location of the dental focal infections at frontal teeth level (right or left) or lateral teeth, no association was found ( $p=0,949$ ).
22. Anterior uveitis due to dental damage is predominant in the age groups between 31- 50 years old.
23. The most common dental focal infections, most frequently involved in anterior uveitis are root residues, followed by the marginal periodontal diseases, the most active being the encapsulated periapical focal infections (old root remnants and apical periodontitis).
24. In 10 patients, it was possible to perform the histopathological examination of the biological product resulted from the dental treatment and it was found out that the onset was acute in a number of 9 patients and insidious in only one patient.
25. Regarding the acute onset of uveitis symptoms in relation to the presence of dental focal infection and visual acuity monitoring from the time of admission and at discharge, it was found that the chronic onset was in direct relation with the steady evolution of visual acuity and with a favourable evolution of the patients in whom the onset was acute.
26. In terms of uveal inflammatory process location, it was found that it affected both eyes in a number of 11 patients, with a greater involvement in the right eye (85 patients) compared to 76 patients with damage to the left eye (table no. 42). From the point of view

of visual acuity, it was found that it was normal in 22 patients with uveitis location in the right eye, but it was low in most patients with damage to the right eye (74.1%).

27. We can say with a certainty of 99% ( $p = 0.000$ ) that the location of uveitis depends on the level of visual acuity, both in the right eye and in the left eye.
28. Visual acuity was aimed at during hospitalization and according to the location of uveitis, so that from the collected and statistically analyzed data, it can be said with an accuracy of 99% ( $p=0,000$ ) that the level of visual acuity on discharge is improved compared to the level of visual acuity upon admission according to uveitis location, this being mainly due to the administered treatment.
29. In terms of uveitis location, it was found that this affected the both eyes in a number of 11 patients, in 85 patients the right eye was damaged, while 76 patients showed left eye damage. Related to the number of days of hospitalization depending on the location of uveal pathology, it cannot be said that there is a statistically significant difference ( $p = 0.703$ ) between the average days of hospitalization and the location of uveitis. Compared to the arithmetic mean of the 172 patients ( $m = 8.48$  days), those with uveitis location in the left eye required a higher length of stay ( $m = 8.83$  days).
30. In terms of laboratory tests made on two samples it was found that all patients were investigated from this point of view.
31. One cannot say that there is an association between uveitis location and the type of treatment ( $p = 0.455$ ). Mention must be made of the fact that all patients were administered anti-inflammatory drugs locally and / or generally.
32. We can say with an accuracy of 95% ( $p = 0.036$  for the right eye,  $p = 0.07$  for the left eye), that there is a significant difference between the number of days of hospitalization and visual acuity difference. Improving visual acuity difference requires a greater number of days of hospitalization.
33. It can be said with an accuracy of 99% ( $p = 0.004$ ), that there is a statistically significant difference between the means of hospitalization days by age groups.
34. Increased prevalence of odonto-periodontal infections found in dental offices of all the examined patients is explained by poor hygiene, a root canal treatment performed incorrectly, untreated caries in due time.
35. The treatment based on the positive diagnosis of certainty was individual, taking into account the peculiarities and particularities of each case.



# Bibliography

1. Singh DR. Essentials of Anatomy for Dentistry Students. Lippincott Williams & Wilkins, 2009.
2. Iliescu A, Gafar M, Cariologie și odontoterapie restauratoare, Editura Medicală, București, 2002.
3. Gopi Krishna V, Suresh Chandra B. Grossman's Endodontic Practice. Lippincott Williams & Wilkins; 2014.
4. Scott GR, Irish JD.(eds). Anthropological Perspectives on Tooth Morphology. Genetics, Evolution, Variation. Liverpool, John Moore university, 2013.
5. Bădescu Adriana, Cărintu Irina, Amălinei Cornelia, Floarea-Strat Alina, Adomicăi Maria. Țesuturi normale. Curs de histologie. Ed.Graphix, Iași 1994.
6. Sobotta, Hammersen. Histologie. Farbatlas der Mikroskopischen Anatomie. Urban & Schwarzenberg, München-Wien-Baltimore, 1985.
7. Kumar S.Textbook of Dental Anatomy and Tooth Morphology, Jaypee Brothers Publishers, 2004.
8. Wheater PR, Burkitt HG, Daniels GV. Functional Histology. Ed. Churchill Livingstone, 1987.
9. Harte S. Dental anatomy coloring book. British Dental Journal, London: Nature Publishing Group, 2011.
10. Koppe T, Meyer G, K. Alt K.W, Brook A, Dean M.C. Comparative Dental Morphology: (Frontiers of Oral Biology). Selected Papers of the 14th International Symposium on Dental Morphology, August 27-30, Greifswald, Germany, 2008.
11. [www.romedic.ro](http://www.romedic.ro).
12. Liebgott B. The Anatomical Basis of Dentistry. 3 ed. Mosby; December 1, 2009.
13. Moore KL, Dalley II AF, Agur AM. Clinically Oriented Anatomy, 6 ed. Softcover North American Edition; 2009.
14. Diculescu I, Doina Onicescu, Popescu LM, Popescu M, Cristina Vidulescu. Histologie medicală. Ed. Medicală, București, 1987.
15. Eanu Nicolae. Histologie (trad. după I.Afanasiev și col.). Ed. Literatura didactică, Chișinău, 1993.

16. Rajkumar K, Ramya R. Textbook of Oral Anatomy, Physiology, Histology and Tooth Morphology. Lippincott Williams & Wilkins; 2012.
17. Cotuțiu Coriolan, Curs de histologie. Litografia IMF Iași, 1986.
18. Stela Roșca, Grosu F, Dura H, Anca Roșca, Moldovan C, Roșca Gh. Curs de Histologie, Vol.1, Ed. Alma Mater, 2001, Sibiu.
19. Stela Roșca, Grosu F, Dura H, Anca Roșca, Moldovan C, Roșca Gh. Curs de Histologie, Vol.2, Ed. Alma Mater, 2002, Sibiu.
20. Grosu F, Dura H, Anca Roșca, Csilla Kovacs, Stela Roșca, Roșca Gh. Lucrări practice de Histologie, vol. I, Ed. Alma Mater, Sibiu, 2001.
21. Grosu F, Dura H, Anca Roșca, Csilla Kovacs, Stela Roșca, Roșca Gh. Lucrări practice de Histologie, vol. II, Ed. Alma Mater, Sibiu, 2001.
22. Drădoiu C, Crișan C. Elemente de histologie și tehnică microscopică. Ed.H.Welther, Sibiu, 1946.
23. <http://learn.dentistry.utoronto.ca/Courseware/Histology/DentalHisto/slide012/>.
24. Stela Roșca, Grosu F, Dura H, Anca Roșca, Moldovan C, Roșca Gh. Curs de Histologie, Vol. III, UMF Tg. Mureș, 2002, Sibiu.
25. Ham AW, Cormack DH. Histology. L.B. Company, 1989.
26. Grosu F, Stela Roșca, Dura H, Anca Roșca, Moldovan C, Roșca Gh. Curs de Histologie generală și specială (pentru studenții Colegiului de Medicină Ed. Alma Mater, Sibiu, 2001.
27. Grosu F, Stela Roșca, Dura H, Anca Roșca, Moldovan C, Roșca Gh. Curs de Histologie generală și specială (pentru studenții Colegiului de Medicină), Ed. Alma Mater, Sibiu, 2001.
28. Currie AW. Basic Histology and Cytology. Ed. Churchill Livingstone, 1988.
29. Jean-Pierre Dadoune, Peter Hadjüski, Jean Pierre Saffroi, Eric Vandrey. Histologie. Ed.Flammarion, Paris, 1990.
30. Goconda Dobrescu, Toni Gheorghiu, Marina Bârsan. Histologie - curs. Ed. II-a. Litografia IMF Iași, 1985.
31. Gardner DL, Dodds TC. Human Histology. Ed. Churchill Livingstone, 1976.
32. <http://pocketdentistry.com/13-dentin-and-pulp/>.
33. Leonhardt H. Human Histology, Cytology and Microanatomy. Georg Thieme Publishers, 1977.

34. Stock Christopher JR, Gulabivala K, Walker Richard T, Goodman Jane R. Color Atlas and Text of Endodontics, Second Edition, Times Mirros, International Publisher Limited. Morby- Wolfe, 1995, pag. 1.
35. Poirier J, Ribadeau Dumas JL. Histologie. Ed. Masson et Cie, Paris, 1988.
36. Alan Stevens, James Lowe (trad. Henri Copin, André Collet, Pierre Validire). Histologie. Ed. pradel-Edisem, 1991.
37. Carlos Junqueira, José Carneiro, Robert Kelley O. Basic Histology. Appleton Lange, 1992.
38. Dumitriu H, Dumitriu S, Dumitriu A. *Parodontologie*, Ediția a IV-a, Editura Viața Medicală Românească, 2006, pag. 40-59.
39. Wolf H, Hassel TM, Color Atlas of Dental Hygiene , Periodontology, Thieme, Stuttgart. New York, 1995, pag. 7-17.
40. Lung T. *Parodontologie clinică*, Editura Cluj- Napoca Star, 2007, pag.20-88.
41. Cotuțiu C, Sârghie M. Histologie. Litografia IMF Iași, 1980.
42. Coujard R, Poirier J, Racadot J. Précis d'Histologie Humaine. Ed. Masson - Paris, New-York, Barcelona, Milan, 1980.
43. Diculescu I, Onicescu D, Rîmniceanu C. Histologie vol.I și II. Ed. Didactică și Pedagogică București, 1971.
44. Gioconda Dobrescu, Mariana Bârza. *Curs de histologie vol.I-II*, ed. II-a, Litografia I.M.F. Iași, 1990.
45. Leson TS, Lesson CR. Histologie. Masson et Cie Éditeurs Paris, 1971.
46. Adriana Minic, Monica Toader Radu, Mureșan VD, Mariana Mărgineanu, Mihaela Mureșan, Alina Neagoe, Mariana Coca. *Curs de Histologie - vol. I. și II.* Litografia U.M.F. Cluj-Napoca, 1992.
47. Poirier J, Ribadeau Dumas JR. Histologie. Ed. Masson-Paris, Milan, Barcelona, Mexico, 1988.
48. Papilian VV, Elena Carpen, Adriana Olinie, Doina Mureșan, Maria-Elena Gocan, Monica Toader-Radu, Mureșan V. *Curs elementar de Histologie.* Litografia IMF Cluj-Napoca.
49. Papilian VV, Roșca GhV. *Tratat elementar de Histologie vol. I. și II.* Ed. Dacia Cluj-Napoca, 1977-1978.
50. Alan Stevens, James Lowe. Histologie. Editura Pradel, 1992.
51. Wheater PR, Burkitt HG, Daniels VG. *Functional Histology. Second Edition.* Churchill-Livingstone. Edinburgh, London, Melbourne, New-York, 1987.

52. Cernea P. *Tratat de Oftalmologie*, Ediția a II-a, Editura Medicală, București, 2002.
53. Pop R. *Oftalmologie*, Editura Cărții de știință, Cluj-Napoca, 1995.
54. <http://www.siumed.edu/~dking2/ssb/NM014b.htm>.
55. <http://colegiultehnicpn.3x.ro>.
56. <http://www.siumed.edu/~dking2/ssb/EE017b.htm>.
57. Page RC. Current understanding of the aetiology and progression of the periodontal disease. *Int Dent J* 1986; 36:153-161.
58. Burlacu V, Cușnir A, Cartaleanu A, Eni A, Zagnat V, Ursu E, Stratu V, Sprânceană E, Costru T, Grosu E, Curteanu L, Scobioală E, Spânu G. Combaterea rațională a proceselor inflamatorii parodontale. *Probleme actuale de stomatologie*, Congresul XII al ASRM, Chișinău, 3-4. 10.2003.
59. Cachovan G, Phark JH, Schön G, Pohlenz P, Platzer U. Odontogenic infections: An 8-year epidemiologic analysis in a dental emergency outpatient care unit. *Acta Odontol Scand.* 2013 May-Jul. 71(3-4):518-24.
60. Daramola OO, Flanagan CE, Maisel RH, Odland RM. Diagnosis and treatment of deep neck space abscesses. *Otolaryngol Head Neck Surg.* 2009 Jul;141(1):123-30.
61. Rasteniene R, Aleksejuniene J, Puriene A. Determinants of Length of Hospitalization due to Acute Odontogenic Maxillofacial Infections: A 2009-2013 Retrospective Analysis. *Med Princ Pract.* 2015. 24(2):129-35.
62. Hodgdon A. Dental and related infections. *Emerg Med Clin North Am.* 2013 May. 31(2):465-80.
63. Kerr DA. Granuloma pyogenicum. *Oral Surg Oral Med Oral Pathol.* 1951;4:158-176.
64. Dahlen G. Microbiology and treatment of dental abscesses and periodontal-endodontic lesions. *Periodontology 2000* 2002;28:(1)206-239.
65. Lopez-Piriz R, Aguilar L, Gimenez MJ. Management of odontogenic infection of pulpal and periodontal origin. *Medicina oral, patologia oral y cirugia bucal* 2007;12(2): E154-159.
66. *Essentials of Oral Pathology*: Jaypee Brothers Medical Publishers; 2011.
67. Seppanen L, Rautemaa R, Lindqvist C, Lauhio A. Changing clinical features of odontogenic maxillofacial infections. *Clinical Oral Investigations* 2010;14(4):459-465.
68. Burnham R, Bhandari R, Bridle C. Changes in admission rates for spreading odontogenic infection resulting from changes in government policy about the dental schedule and remunerations. *Br J Oral Maxillofac Surg* 2011;49(1):26-28.

69. Krishnan V, Johnson JV, Helfrick JF. Management of maxillofacial infections: a review of 50 cases. *Journal of Oral and Maxillofacial Surgery: Official Journal of the American Association of Oral and Maxillofacial Surgeons* 1993;51(8):868-873.
70. Wang J, Ahani A, Pogrel MA. A five-year retrospective study of odontogenic maxillofacial infections in a large urban public hospital. *Int J Oral Maxillofac Surg* 2005;34(6):646-649.
71. Krebs KA, Clem DS 3rd. Guidelines for the management of patients with periodontal diseases. *J Periodontol.* 2006 Sep. 77(9):1607-11.
72. [www.infodentis.com](http://www.infodentis.com).
73. Morari I. Afecțiuni endodontice. Noțiuni clinico-terapeutice actuale, Editura Tehno-Media, 2008.
74. Mortensen M, Winthee JE, Birn H. Periapical granulomas and cysts. An investigation of 1600 cases. *Scand J Dent Res* 1970, 78:241-250.
75. Rosai and Ackerman s. *Surgical Pathology*, Mosby, 2011, 1:280-285.
76. Mills SE, Cooper PH, Fechner RE. Loobular capillary hemangioma: the underlying lesion of pyogenic granuloma. *Am J Surg Pathol* 1980;4:471-479.
77. Sin A. Mic tratat de patologie buco-maxilo-facială, Edit. Veritas, Tg-Mureș, 1998, 35-40.
78. Moursh F, A roentgenographic study of dentigerous cysts. *Oral Surg Oral Med Oral Pathol* 1964,18:466-473.
79. Minsk L. Bone Replacement Grafts for Periodontal Regenerations, *Compendium* 26 (9) – 676-682, Sept. 2005.
80. Morari I, Ștețiu A, Silivășan V, Diagnosticul bolii parodontale.Principii generale de abordare, *Dento Medica*, Iași, nr.2+3, 2002.
81. Roman A, Parodontopatii asociate factorilor sistemici, implicații terapeutice, Editura Todesco, Cluj, 2001.
82. Lungu I, Parodontologie și boala de focar, Tipografia UMF Cluj, 1995.
83. White SC, Pharoah MJ. Cysts of the jaws. White SC, Pharoah MJ, eds. *Oral Radiology: Principles and Interpretation*. 5th ed. St. Louis, Mo: Mosby; 2004.
84. Olinescu R, Metode biochimice de laborator clinic, Editura Cerma, București, 2001.
85. Sato FR, Hajala FA, Freire Filho FW, Moreira RW, de Moraes M. Eight-year retrospective study of odontogenic origin infections in a postgraduation program on oral and maxillofacial surgery. *Journal of Oral and Maxillofacial Surgery: Official Journal of the American Association of Oral and Maxillofacial Surgeons* 2009;67(5):1092-1097.

86. Uluibau IC, Jaunay T, Goss AN. Severe odontogenic infections. *Aust Dent J* 2005;50(4 Suppl 2):S74-81.
87. Antunes AA, de Santana Santos T, de Carvalho RW, Avelar RL, Pereira CU, Pereira JC. Brain abscess of odontogenic origin. *J Craniofac Surg* 2011;22(6):2363-2365.
88. Baqain ZH, Newman L, Hyde N. How serious are oral infections? *J Laryngol Otol* 2004;118(7):561-565.
89. Albilal JB, Humber CC, Clokie CM, Sandor GK. Lemierre syndrome from an odontogenic source: a review for dentists. *Journal (Canadian Dental Association)* 2010;76:47.
90. Bucak A, Ulu S, Kokulu S, Oz G, Solak O, Kahveci OK, et al. Facial paralysis and mediastinitis due to odontogenic infection and poor prognosis. *J Craniofac Surg* 2013;24(6):1953-1956.
91. Sakamoto H, Aoki T, Kise Y, Watanabe D, Sasaki J. Descending necrotizing mediastinitis due to odontogenic infections. *Oral Surg, Oral med, Oral pathol, Oral radiol, Endodon* 2000;89(4):412-419.
92. Stăniceanu F. Elemente de patologie orală, Edit. Medicală, București, 2001, pag. 61-65.
93. Brennan MT, Runyon MS, Batts JJ, Fox PC, Kent ML, Cox TL, et al. Odontogenic signs and symptoms as predictors of odontogenic infection: a clinical trial. *J Am Dent Assoc (1939)* 2006;137(1):62-66.
94. Cachovan G, Phark JH, Schon G, Pohlenz P, Platzer U. Odontogenic infections: an 8-year epidemiologic analysis in a dental emergency outpatient care unit. *Acta odontologica Scandinavica* 2013;71(3-4):518-524.
95. Dailey YM, Martin MV. Are antibiotics being used appropriately for emergency dental treatment? *Br Dent J* 2001;191(7): 391-393.
96. Goncalves L, Lauriti L, Yamamoto MK, Luz JG. Characteristics and management of patients requiring hospitalization for treatment of odontogenic infections. *J Craniofac Surg* 2013;24(5):458-462.
97. Saito CT, Gulinelli JL, Marao HF, Garcia IR Jr, Filho OM, Sonoda CK, et al. Occurrence of odontogenic infections in patients treated in a postgraduation program on maxillofacial surgery and traumatology. *J Craniofac Surg* 2011;22(5): 1689-1694.
98. Fedorowicz Z, van Zuuren EJ, Farman AG, Agnihotry A, Al-Langawi JH. Antibiotic use for irreversible pulpitis. *The Cochrane Database of Systematic Reviews* 2013;(12):1-25.
99. Matthews RW, Peak JD, Scully C. The efficacy of management of acute dental pain. *Br Dent J* 1994;176(11):413-416.

100. Chunduri NS, Madasu K, Goteki VR, Karpe T, Reddy H. Evaluation of bacterial spectrum of orofacial infections and their antibiotic susceptibility. *Annals of Maxillofac Surg* 2012;2(1):46-50.
101. Deschenes J, Murray PI, Rao NA, et al. International Uveitis Study Group (IUSG): clinical classification of uveitis. *Ocular Immunology and Inflammation*. Jan-Feb 2008. 16:1-2.
102. Rosenbaum JT, George RK. Uveitis. *Current Ocular Therapy* 5. 2000. 519-21.
103. JJ Kanski, *Clinical Ophthalmology. A systematic approach*, 6-th Edition, 2007.
104. Merck Manuals: Uveitis. <http://www.merck.com/mmhe/sec20/ch232/ch232a.html>.
105. Yanoff and Duker. Uveitis and other intraocular inflammations. *Ophthalmology*. 3rd ed. Mosby; 2008.
106. Jabs DA, Nussenblatt RB, Rosenbaum JT; Standardization of Uveitis Nomenclature (SUN) Working Group. Standardization of uveitis nomenclature for reporting clinical data. Results of the First International Workshop. *Am J Ophthalmol*. Sept 2005. 140:509-16.
107. McCannel CA, Holland GN, Helm CJ, Cornell PJ, Winston JV, Rimmer TG. Causes of uveitis in the general practice of ophthalmology. UCLA Community-Based Uveitis Study Group. *Am J Ophthalmol*. 1996 Jan. 121(1):35-46.
108. ZF. Saadia, Hampton Roy, Sr, Uveitis classification, Updated: Mar 26, 2014.
109. Madow B, Galor A, Feuer WJ, Altaweel MM, Davis JL. Validation of a photographic vitreous haze grading technique for clinical trials in uveitis. *Am J Ophthalmol*. 2011 Aug. 152(2):170-176.e1.
110. Jabs DA, Nussenblatt RB, Rosenbaum JT. Standardization of uveitis nomenclature for reporting clinical data. Results of the First International Workshop. *Am J Ophthalmol*. 2005 Sep. 140(3):509-16.
111. Deschenes J, Murray PI, Rao NA, et al. International Uveitis Study Group (IUSG): clinical classification of uveitis. *Ocular Immunology and Inflammation*. Jan-Feb 2008. 16:1-2.
112. Trusko B1, Thorne J, Jabs D, Belfort R, Dick A, Gangaputra S, et al. The Standardization of Uveitis Nomenclature (SUN) Project. Development of a clinical

- evidence base utilizing informatics tools and techniques. *Methods Inf Med.* 2013 May. 7;52(3):259-65.
113. Okada AA, Jabs DA. The standardization of uveitis nomenclature project: the future is here. *JAMA Ophthalmol.* 2013 Jun. 131(6):787-9.
  114. Nalcacioglu-Yüksekkaya P, Ozdal PC, Teke MY, Kara C, Ozturk F. Presumed herpetic anterior uveitis: a study with retrospective analysis of 79 cases. *Eur J Ophthalmol.* 2013 Nov 20. 24(1):14-20.
  115. Sanghvi C, Bell C, Woodhead M, Hardy C, Jones N. Presumed tuberculous uveitis: diagnosis, management, and outcome. *Eye (Lond).* 2011 Apr. 25(4):475-80.
  116. McCannel CA, Holland GN, Helm CJ, Cornell PJ, Winston JV, Rimmer TG. Causes of uveitis in the general practice of ophthalmology. UCLA Community-Based Uveitis Study Group. *Am J Ophthalmol.* 1996 Jan. 121(1):35-46.
  117. Baatz H, Pleyer V, Thiel HJ., Hammer C, In vivo study of leukocyte-endothelium interaction in endotoxine-induced uveitis, *Investigative Ophthalmology & Visual Science.* 36 (10) : 1960-7, 1995 September.
  118. Nussenblatt RB, Whitcup SM. Uveitis. Fundamentals and Clinical Practice. 3rd ed. Mosby-Year Book; 2003.
  119. Tessler H. Classification and symptoms and signs of uveitis. Duane T, ed. *Clinical Ophthalmology.* New York, NY: Harper and Row; 1987. 1-10.
  120. Abderrahim K, Chebil A, Falfoul Y, Bouladi M, Matri LE. Granulomatous uveitis and reactive arthritis as manifestations of post-streptococcal syndrome. *Int Ophthalmol.* 2012 Sep 18.
  121. Islam N, Pavesio C. Uveitis (acute anterior). *Clin Evid (Online).* November 2009. 04:705.
  122. Kamal S, Kumar R, Kumar S, Goel R. Bilateral Interstitial Keratitis and Granulomatous Uveitis of Tubercular Origin. *Eye Contact Lens.* 2013 Mar 27.
  123. Wyatt HJ, The form of human pupil, *Vision Research,* 35 (4) : 2021-36, Jul. 1995.
  124. Yawn BP, Wollan PC, St Sauver JL, Butterfield LC. Herpes zoster eye complications: rates and trends. *Mayo Clin Proc.* 2013 Jun. 88(6):562-70.
  125. Justin P, Ehler and Chirag P Shah, *The Wills Eye Manual, Office and Emergency Room Diagnose and Treatment of Eye Disease, Fifth Edition,* 2008.



126. Forester JV, Okada AA, BenEzra D, et al. Posterior Segment Intraocular Inflammation Guidelines. The Hague: Kugler; 1998.
127. Sheppard JD. Posterior uveitis. *Ophthalmol Clin North Am.* 1993. 6:1.
128. BenEzra D, Ohno S, Secchi AG, et al. Anterior Segment Intraocular Inflammation Guidelines. London: Martin Dunitz; 2000.
129. Sheppard JD, Nozik RA. Practical diagnostic approach to uveitis. Duane JA, Jaeger EW, ed. *Duane's Clinical Ophthalmology.* 1989. Vol. 4.
130. Smith RE, Nozik RA. *Uveitis: A Clinical Approach to Diagnosis and Management.* 2nd ed. Baltimore: Williams & Wilkins; 1988.
131. Abad S, Seve P, Dhote R, Brezin AP. [Guidelines for the management of uveitis in internal medicine]. *Rev Med Interne.* 2009 Jun. 30(6):492-500.
132. Wirbelauer C. Management of the red eye for the primary care physician. *Am J Med.* 2006 Apr. 119(4):302-6.
133. Lyon F, Gale RP, Lightman S. Recent developments in the treatment of uveitis: an update. *Expert Opin Investig Drugs.* 2009 May. 18(5):609-16.
134. Lim LL, Smith JR, Rosenbaum JT. Retisert (Bausch & Lomb/Control Delivery Systems). *Curr Opin Investig Drugs.* 2005 Nov. 6(11):1159-67.
135. Dunne JA, Travers JP. Topical steroids in anterior uveitis. *Trans Ophthalmol soc UK.* 1979. 99(4):481-4.
136. Foster CS, Alter G, DeBarge LR, Raizman MB, Crabb JL, Santos CI, et al. Efficacy and safety of rimexolone 1% ophthalmic suspension vs 1% prednisolone acetate in the treatment of uveitis. *Am J Ophthalmol.* 1996 Aug. 122(2):171-82.
137. Jabs DA, Rosenbaum JT, Foster CS, et al. Guidelines for the use of immunosuppressive drugs in patients with ocular inflammatory disorders: recommendations of an expert panel. *Am J Ophthalmol.* 2000 Oct. 130(4):492-513.
138. Jap A, Chee SP. Immunosuppressive therapy for ocular diseases. *Curr Opin Ophthalmol.* 2008 Nov. 19(6):535-40.