

UNIVERSITY „LUCIAN BLAGA” SIBIU
FACULTY OF MEDICINE “VICTOR PAPILIAN”

Field: Medicine

Specialized in: Orthopaedics -Traumatology

**MODERN THEORIES OF STIMULATING
CONSOLIDATION OF DIAPHYSEAL
FRACTURES OF THE LOWER LIMB**

SUMMARY OF THE PhD THESIS

Scientific advisor:
Professor **Ioan Baier**, PhD

PhD student:
Adrian Lupean

SIBIU 2013

I.7 Non Union Factors.....	33
Chapter II CLASSIFICATION OF TIBIAL DIAPHYSEAL FRACTURE.....	35
Chapter III THERAPEUTIC ALGORITHM IN OPEN DIAPHYSEAL TIBIAL FRACTURES.....	47
III.1 Treatment Principles at the Accident Site.....	47
III.2 Treatment Principles in the Emergency Room.....	48
III.3 Intraoperative Therapeutic Conduct	50
III.3.1 Mechanical Hygiene.....	50
III.3.2 Chemical Hygiene.....	50
III.3.3 Surgical Hygiene	51
III.3.4 Stabilisation of the Fracture Site.....	52
III.3.5 Wound Closure.....	57
III.3.5.1 Methods of Managing Wound Closure.....	58
III.3.5.1.1 Primary Suture.....	58
III.3.5.1.2 Secondary Suture.....	58
III.3.5.1.3 Surgical Plastic Treatment of Fractures.....	59
III.3.5.1.3.1 Free Split Skin Grafts/Free flaps Surgery.....	59
III.3.5.1.3.2 Local flaps.....	59
III.3.5.1.3.3 Free flaps.....	60
Chapter IV MODERN TREATMENT METHODS TO STIMULATE BONE FRACTURE HEALING.....	61
IV.1 Biological Methods to Stimulate Fracture Healing.....	61
IV.1.1 Local Biological Methods to Stimulate Fracture Healing.....	61
IV.1.1.1 Local Biological Osteoconductive Methods to Stimulate Fracture Healing.....	62
IV.1.1.1.1 Autogenous Bone Graft.....	62
IV.1.1.1.1.1 Autogenous Cortical and Cancellous Bone Grafting.....	63
IV.1.1.1.1.2 Vascularized Autogenous Bone Graft.....	63
IV.1.1.1.1.3 Bone Transport.....	64
IV.1.1.1.2 Allogeneic Bone Graft	64
IV.1.1.1.3 Heterogeneous Bone Grafts	64
IV.1.1.1.4 Mesenchymal Stem Cells.....	65
IV.1.1.2 Biological Methods to Stimulate Local Osteoconductive Fracture.....	66
IV.1.1.2.1 Resorbable Biomaterials as Bone Graft Substitutes....	67
IV.1.1.2.2 Bioactive ceramic as bone substitute.....	69
IV.1.1.2.3 Bio-inert ceramic substitutes.....	70
IV.1.1.2.4 The Polymers.....	70
IV.1.1.3 Local Biological Osteogenic Methods to Stimulating Fracture Healing.....	70
IV.1.1.3.1 Bone Morphogenetic Proteins (BMPs)	71
IV.1.1.3.2 Growth Factor-Beta (TGF-β).....	73
IV.1.1.3.3 Platelet-Derived Growth Factor (PDGF)	74
IV.1.1.3.4 Vascular endothelial growth factor (VEGF).....	74
IV.1.2 Systemic Methods to Stimulate Bone-Building.....	75

IV.2 Biomechanical Methods to Stimulate Bone Fracture Healing.....	75
IV.2.1 Osteosynthesis-Importance of Osteosynthesis Type in Fracture Healing.....	75
IV.2.2 Mechanical Stimulation Factors in Fracture Healing.....	77
IV.3 Biophysical Methods of Stimulating Fracture Healing.....	78
IV.3.1 Electrical Stimulation in Fracture Healing.....	78
IV.3.2 Ultrasounds Stimulation in Fracture Healing.....	79
THESIS.....	81
Chapter V RETROSPECTIVE STUDY ON OPEN FRACTURES OF THE LOWER LIMB BASED ON ORTHOPAEDIC CASUISTRY 2006-2008.....	81
V.1 Introduction to the Research.....	81
V.2 The Purpose of the Research	82
V.3 Materials and Methods used during the Research.....	82
V.4 Research Findings.....	83
V.5 Discussions and Conclusions.....	101
Chapter VI THE INFLUENCE OF HIGH FREQUENCY ULTRASOUND THERAPY ON PSEUDOARTHROSIS AND DELAYED UNION	105
VI.1 Introduction to the Research	105
VI.2 Materials and Methods used during the Research	106
VI.3 Research Findings	111
VI.4 Clinical and Radiological Aspects/Features in Studied Cases...	116
VI.5 Conclusions	118
Chapter VII THE INFLUENCE OF ULTRASOUND THERAPY IN THE EVOLUTION OF OPEN TIBIAL SHAFT FRACTURES.....	120
VII.1 Introduction to the Research.....	120
VII.2 The purpose of the Research.....	120
VII.3 Materials and Methods used during the Research.....	121
VII.4 Research Findings and Discussions	131
VII.5 Clinical and Radiological Aspects/Features in studied cases (selection).....	157
VII.6Conclusions.....	167
Chapter VIII CT SCANNING USED IN IN THE EVOLUTION AND ASSESSMENT OF OPEN FRACTURES OF THE TIBIAL DIAPHYSIS	171
VIII.1 Introduction to the Research	171
VIII.2 The Purpose of the Research	171
VIII.3 Materials and Methods used during the Research	177
VIII.4 Research Findings and Discussions	177
VIII.5 Conclusions	189
Bibliography.....	190

Summary of the general overviews

Antiquity has shown that there has been an early interest in the study of fracture repair and consolidation, generated by some doubts on bone regeneration capacity. A bone fracture triggers a series of complex repair stages, based on a strict temporospatial sequence that ends in the union of bone fragments without a scar.

Chapter I-“Callus-Pathophysiology” focuses on fracture consolidation mechanisms, early and contemporary insights on callus formation, evolution phases on callus formation and important factors that have a strong influence on fracture healing.

Chapter II-“Classification of tibial diaphyseal fractures” is a synthesis of tibial diaphyseal fractures carried out since early times up to date. Moreover, a special interest is shown to the clinical-therapeutical importance, relevance of evolution, and the prognosis of most commonly used classifications in everyday practice.

Chapter III-„ Therapeutic algorithm in Open Diaphyseal Tibial Fractures” highlights important phases in open diaphyseal lower leg fractures therapy. Attention is shown to ethics at the scene of the accident, in the emergency room and operating room. This section is a detailed description of the treatment process and of the methods made use of while managing fracture/wound sites closure with the positive and negative aspects involved. Open fracture repair is a complex process due to lesion complexity and trauma, and needs a multidisciplinary team: an anaesthesia and intensive care specialist, surgeon, vascular surgeon, neurosurgeon, plastic surgeon, orthopaedic surgeon)

Chapter IV-„ Modern Treatment Methods to Stimulate Bone Fracture Healing” is a thorough presentation of the methods that stimulate fracture repair, that highlights up-to-date procedures used in everyday practice and experimental ones. Thus, these methods have been classified as it follows:

- Biological methods
- Biomechanical methods
- Biophysical methods

Keywords: open fracture, fracture healing, pseudarthrosis, cold ultrasound, tibia, callus

Summary of the thesis

CHAPTER V

RETROSPECTIVE STUDY ON OPEN FRACTURES IN THE LOWER LIMB BASED ON ORTHOPAEDIC CASUISTRY 2006-2008

V.1 Introduction to the research

A successful evolution of open fractures in the lower limb that does not involve any risks depends on a correct treatment that is carried out taking into consideration all phases, starting with providing first aid at the scene, during transportation and especially after hospitalization. The ideal hospital is one that provides specialized modern technical equipment and an experienced multidisciplinary team. The team will keep a constant contact with the patient and re-evaluate the patient periodically in order to choose the appropriate therapeutic techniques for every evolution phase.

V.2 The purpose of the research

This study aims to provide a correct interpretation of the lesion degree, of the sequence of stages, the quality of care during the treatment period, that are important factors in achieving healing of open fractures in the lower limb without risks or complications.

V.3 Materials and methods used during the research

The retrospective study has been conducted at the Clinical County Emergency Hospital from Sibiu, in the Clinical Department Of Orthopaedics and Traumatology and includes all cases of open fractures in the lower leg bones between 2006-2008. The study does not include patients with open fractures of the lower leg strictly localized to the proximal or distal epiphysis.

The current study has made use of the following documents to collect the necessary data:

- ✓ The database of Orthopaedics and Traumatology Department (at that time)
- ✓ Observation sheets of the patients
- ✓ Operating room register
- ✓ Scans from the archive

V.4 Research results/findings

Between 2006-2008, at the Clinical County Emergency Hospital from Sibiu, in the Clinical Department Of Orthopaedics and Traumatology, 5108 patients have been hospitalized, and a number of 224 patients presented diaphyseal fractures of the

lower leg bones. Only 48 of these patients suffered from open fractures of the lower leg bones, the rest of the patients-176 presented closed fractures. Over a period of three years the study has shown the following information:

- 2006-76 patients out of whom only 20 cases of open fracture;
- 2007-77 patients out of whom 10 cases of open fracture;
- 2008-71 patients out of whom 10 cases of open fracture;

From 48 studied cases, 38(79%) were men. The average age of the subjects in the current case is 44, the youngest patient was 18 years old, the eldest 90 years old. The ethiology of open fractures is varied: traffic accidents(52%), household accidents(27%), accidents at work(11%), violence cases(4%).

Without taking into consideration 5 cm proximal and distal parts that correspond to the epiphysis of the lower leg bones, the diaphysis was separated in three equal parts that have established the main fracture site closure. Those three diaphyseal fractures were named: 1/3 proximal fraction, 1/3 middle, 1/3 distal. The classification of the patients under study based on the main fracture site closure: 1/3 proximal diaphyseal fraction-10 cases ,1/3 middle-26 cases, 1/3 distal-12 cases.

The classification of cases of open fractures of the lower leg takes into consideration skin lesions and soft-tissue injury and is based on the well-known study of Gustilo-Anderson:I-20 cases, II 19 cases, IIIA 7 cases, IIIB 2 cases, IIIC 0 cases.

A part of the open fractures of the lower leg have occurred in a plurilesional or polytraumatic context. Thus, 15 cases presented other lesions,5 cases presented an association of multiple injuries in the open fracture of the lower leg. Perilesional associations found in the research are presented in table 1.

Table 1.Trauma related diagnoses

Association lesion	Number of cases
Craniocerebral trauma	5
Thoracic trauma	4
Maleolar fracture	1
Tibial plateau fracture.	1
Scapula fracture	1
Metatarsal fracture	1
Foreleg amputation trauma	1
Craniofacial trauma	1
Scapulo-humeral luxation	1
Clavicle fracture	1
Distal radial epiphyseal fracture	1
Open femoral fracture	1
Proximal humerus fracture	1

Treatment and prognosis of open lower limb fractures is strongly influenced by the biological status of the patient, and, thus patient's medical history has been taken into consideration. In the case studies, related diseases have been met in 12 cases:

arterial hypertension (6), diabetes mellitus (3), ischemic heart disease (3), chronic hepatitis B (1), homolateral ankle arthrosis (1) COPD (1), chronic atrial fibrillation (1).

Fracture site type has been interpreted in terms of the AO ASIF classification. Taking into consideration all factors this classification is based upon, 27(56%) of the subject cases presented a simple fracture (42A-based on AO-ASIF classification), and 21(44%) presented a comminuted fracture (42B or 42C-based on AO-ASIF classification).

Therapeutic treatment plan has been designed based on different lesions taking in consideration the appropriate stages in terms of the local lesion degree, associated lesions and clinical context of contusions and trauma.

Initial assessment and stabilisation of fracture included the following aspects:

- Plaster cast immobilisation-8 cases;
- Trans-calcaneal extension-33 cases;
- External fixation with osteosynthesis-7 cases.

Previous data has shown that initial stabilisation of fracture that was used more often is the trans-calcaneal extension, while plaster cast immobilisation was used only in type I and II open fractures, and external fixation was used in type III open fractures.

Final stabilisation of the fracture included:

- Orthopaedic methods;
- Surgical methods.

Definitive stabilisation of the fracture included:

- immobilisation of the fracture with the initial plaster cast until fracture consolidation;
- trans-calcaneal conversion(after a previous scanning of the fracture)in plaster cast immobilisation until fracture healing;

Definitive surgical stabilisation of the fracture made use of different methods:

- Centro-medular nailing osteosynthesis;
- External fixation osteosynthesis;
- Screw and plate osteosynthesis. (table 2)

Table2 Type of Final stabilisation of the fracture

Type of Final stabilisation of the fracture	No. Of cases	Method	No. of cases
Orthopaedic	17	immobilisation of the fracture with the initial plaster cast until fracture consolidation	8
		trans-calcaneal conversion in plaster cast immobilisation	9
Surgical	31	Centro-medular nailing osteosynthesis	22
		External fixation osteosynthesis	8
		Screw and plate osteosynthesis	1

Definitive surgical fracture stabilisation methods have been differentiated (table 3):

- intramedullary Kuntscher nailing osteosynthesis without diaphyseal reaming-22 cases;
- reamed and locked intramedullary nailing osteosynthesis-1 case,
- plate and screws osteosynthesis-1 case;
- external fixation osteosynthesis-7 cases.

Table 3 Definitive surgical fracture stabilisation methods

Definitive surgical fracture stabilisation method	Type I	Type II	Type IIIA	Type IIIB
Intermedullary nailing	12	8	3	0
Plate and screws	1	0	0	0
External fixation (FE)	1	2	2	2

Management of posttraumatic wounds and skin defects includes multiple and complex interventions, and sometimes requires collaboration with a plastic surgeon. (fig. no. 1)

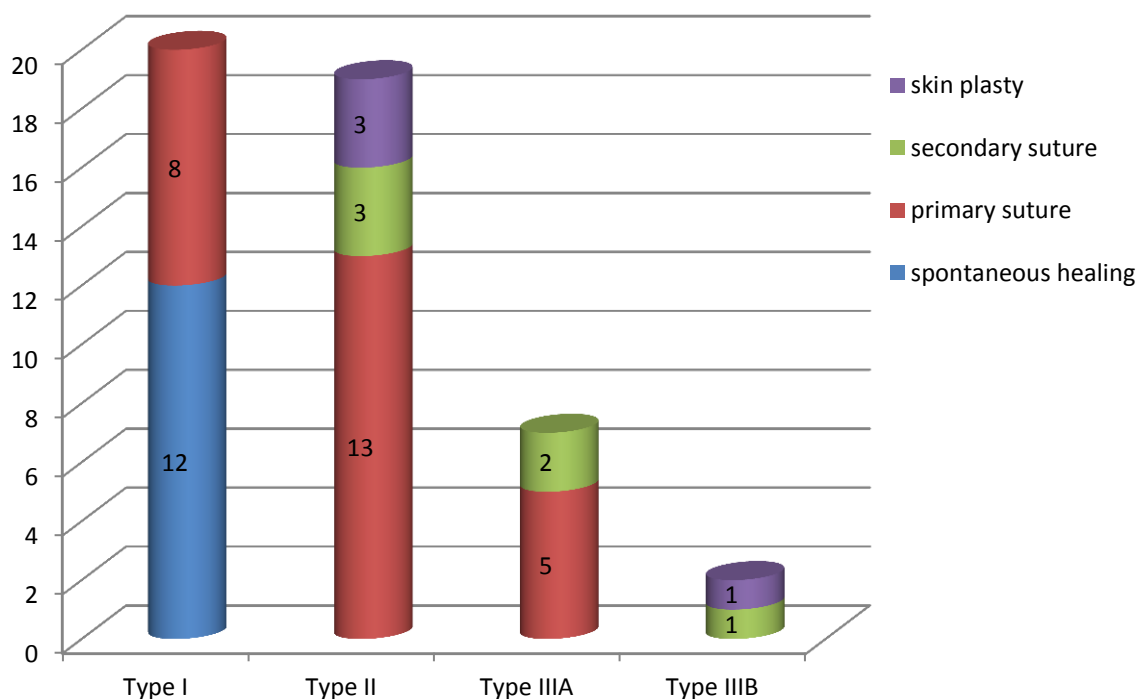


Fig. no. 1 Case classification based on the procedures used to close the fracture site

Study cases have reached a number of 1005 hospitalisation days, with an average of 21 days, and a period that spanned between 7 and 57 days. This is a classification based on the total and average hospitalisation period. (table no. 4):

Table no. 4 Classification of cases based on hospitalisation period

Gustillo-Anderson classification	Total number of hospitalisation days	Average number of hospitalisation days
Type I	301	15
Type II	460	24,2
Type III	244	27,1

Based on Gustillo-Anderson classification ,taking into consideration lesion degree, the average duration of antibiotic prophylaxis has shown the following:

- ✓ Type I-7,8 days;
- ✓ Type II-10,9 days;
- ✓ Type III-15,6days.

Studied cases involved postoperative immediate and late complications. An analysis of the database of the hospital has highlighted the fact that no extreme complications,such as pulmonary embolism or shock occurred. As far as immediate local complications are concerned, there was not any record of compartment syndrome and acute osteomyelitis. In 9 of the studied cases immediate complications occurred:

- ✓ Primary suturing haematoma of the contused wound– 2 cases (1-type I, 1-type II);
- ✓ Traumatic skin necrosis-4 cases(2-Type I,1-Type IIIA,1 Type IIIB);
- ✓ Infection of wound/contusion-3 cases (2-Type II,1 Type IIIB).

These complications have ben solved making use of the following methods:

- ✓ Primary suturing haematoma of the contused wound-surgical evacuation;
- ✓ Traumatic skin necrosis- necrectomy and secondary suture;
- ✓ Infection of wound/contusion- anti biotherapy according to the antibiogram until wound sterilisation.

Bacteriological examination of the isolated germs from the infected wound has shown the presence of the following types of bacteria:

- ✓ Acinetobacteria– 1 case of type IIIB fracture;
- ✓ Staphylococcus aureus – 1case of type II fracture;
- ✓ Klebsiella Oxytoca – 1 case of type II fracture.

Immediate local complications that have occurred have been successfully solved after carrying out the appropriate treatment.

Assessment of postoperative immediate and late complications was based on the post-operative hospitalisation periods, that aimed to solve a complication or just to extract the osteosynthesis material. Studied data has shown that here were no cases of malunion or late postoperative infection (osteitis).Some of the complications that have been traced in the case of post-operative hospitalisation periods are:

- ✓ intramedullary rod migration - 1 case (type IIIA);
- ✓ Infection of the external fixator rod -1 case (type IIIA);
- ✓ nonunion -3 cases (1 case-type I, 1 case-type II, 1 case-type IIIA).

These complications have been solved making use of the following methods:

- ✓ migration of intramedullary rod – reintroduction;
- ✓ infection of the external fixator-therapy based on antibiotics according to the antibiogram;
- ✓ nonunions:
 - 1 case – use of cancellous graft + plate and screws osteosynthesis;
 - 2 cases - intramedullary reaming of tibia and nailing

V.5 Discussions and Conclusions

1. Analysing open fracture of the lower limb over the studied period, it is to be noticed the fact that the number of cases increased in 2006 and 2008, if compared with the number of cases registered in 2007. However, the number of cases of open fracture out of the total number of lower limb hospitalisations is definitively a considerable one between 2006-2008.
2. As far as sex differentiation is concerned, the number of male patients is bigger than the number of female patients. This issue can be easily explained because male subjects are frequently exposed to higher risk activities.
3. An analysis based on age group distribution indicates a bigger number of cases of open fracture of lower leg for patients up to 60 years, who live an active life.
4. Traffic accidents are the main cause of open fracture of lower leg (more than half of the cases under study). However, varied household accidents register a great number in open fracture of lower leg ethiology.
5. The leg bone is exposed to lesion due to its superficial integumentary position and lesion is frequently located along the 1/3 middle and especially the verge of 1/3 and 1/3 distal, due to the fact that this is the part of the bone shows minimal strength, its risk-prone shape, and because it is considered to be the narrowest section of the tibial diaphysis.
6. From an ethiological point of view, although traffic accidents are the major cause of open fractures of the lower leg, the type of fractures based on the Gustilo-Anderson classification, which have been frequently met are type I and II (79%), due to the action of a minor or medium intensity lesion factor.
7. Perfectly aware of the main ethiology of producing open fractures lower leg bone, one can easily associate other lesions in a plurilezional or politraumatic context. The presence of other lesions at a certain distance from the fracture site shows the violent character of the lesion factor that acted upon this segment. Moreover, this idea is reinforced by the frequent association with other fractures, such as type IIIA and IIIB open fractures.
8. Important diseases from the patient's medical history can influence therapy, prognosis, or can even force the trauma surgeon to take into consideration reconstruction or amputation of the affected limb.

9. Condition of the fracture site (simple or comminute) has played an important role in fracture site stabilisation, and, thus the AO-ASIF classification is very useful in open fracture in the lower leg.
10. Setting main objectives immediately after admission of a case of open fracture in the lower leg, even in a plurilesional or politraumatic context, is the cornerstone of correct therapeutic attitude and success of the treatment applied to the patient.
11. Nowadays initial stabilisation of the fracture site –mainly open fractures type I and II, based on Gustillo-Anderson classification-by making use of orthopaedic methods(plaster cast or trans-calcaneal conversion), denotes a cautious and expectative attitude, and also thorough observation of the future evolution of associated local lesions.
12. Definitive surgical stabilisation of the fracture site is met in majority of the studied cases(75%),and the latest trends in the treatment of open fractures of the lower leg are highlighted.
13. The most frequent case is intramedullary nailing osteosynthesis (74%),as it is the latest therapy method of treatment of open fractures of the lower leg, type I, II,and IIIA, based on Gustillo-Anderson classification.
14. One of the main objectives in therapy is to transform an open fracture to close fracture, which consists of a process that starts in the very first moment of admission, by means of primary suture of traumatic wounds or rapid spontaneous cicatrisation of punctiform points(79%).
15. Open fractures of lower leg generally ask for a longer hospitalisation period with important material and human costs. The average hospitalisation period is definitively influenced by the lesion degree of soft tissue-found in the Gustillo-Anderson classification-and it increases constantly as it is directly connected to the degree of lesions. The previous statement is also valid for the period of time between the moment of hospitalisation and definitive fracture site osteosynthesis, and for carrying out an average antibiotic prophylaxis therapy.
16. Sometimes initial stabilisation of the fracture site may become a definitive one if the appropriate clinical, biomechanical and prognosis criteria are met. Thus, in 7 of the understudy cases(26%), maintaining the internal fixator introduced in the first hospitalisation phase was the final decision, and only in one of the cases there were some complications of osteitis at the external fixator rods associated with closed non-union.
17. There have been some immediate local complications, but of reduced intensity and without any clinical-evolutionary influence on the long term. One case may be mentioned, though, of an immediate local complication (skin necrosis of the wound) and a late local complication (closed pseudoartrosis). Iatrogenic, and Klebsiella Oxytoca infection of the wound may also be mentioned in two of the cases, but these situations have been soled by applying targeted antibiotic therapy.

18. There have been rare late local complications (12%), and these have been solved by surgical methods. Late complication occurred in one case, and it was manifested by osteitis at the external fixator rods.

CHAPTER VI

THE INFLUENCE OF HIGH FREQUENCY ULTRASOUND THERAPY ON PSEUDOARTHROSIS AND DELAYED UNION

VI.1 Introduction to the research

There are several factors that may influence fracture healing, or that can even prevent it. Some of these factors are the characteristics of the fracture and patients' medical history, which can cause pseudoarthrosis.

Nowadays, there are several treatment options of pseudoarthrosis :

- ✓ surgical treatment;
- ✓ conservative treatment;
- ✓ electric stimulation;
- ✓ shockwave therapy;
- ✓ low intensity and high frequency pulsed ultrasound therapy.

Therapeutic effect of ultrasounds in treatment and consolidation of pseudoarthrosis depends on their intensity. Low intensity ultrasounds, accompanied by a high pulsed frequency, acts on fracture healing during daily irradiation. The pressure that results during this process produces vibration of mesenchymal cell walls, and causes an acceleration of cellular metabolism. Besides faster transformation of mesenchymal cells into osteoblasts and then osteocytes, it was found that sonic impulses also act on bone canaliculi opening, that help calcium ions to enter easier in bone cells. (94,118,181)

VI.2 Materials and methods used during the research

The study included late bone consolidation and delayed non-unions resulting from fractures treated in the Clinical Department Of Orthopaedics and Traumatology Orthopaedics, Emergency County Hospital of Sibiu between 2009-2012.

Study inclusion criteria are:

- patients with non-union regardless of bone interest or type of initial treatment of fracture;
- patients aged 18 years and more;
- at least 3 months after the fracture producing;
- absence of a stimulating bone healing treatment method at least two months before starting ultrasound therapy;
- absence of radiographic healing (minimum three cortical bridges) of the fracture that was visible on radiographs made at least two incidents.

Study exclusion criteria:

- abuse of alcohol, tobacco or drugs of the patient;
- presence of neuropathy, active malignancy or chronic metabolic diseases, that affect bone formation;
- septic non-union with active infection;
- treatment with hormones, steroids, anticoagulants or bisphosphonates.

Patients included as subjects of the study have agreed with applying cold ultrasound therapy as a method of treatment pseudoarthrosis or delayed union, diagnosed both clinically and radiologically.

Ultrasounds treatment was performed using a portable device, that is a version of the devices that stimulate new bone production, using low intensity ultrasound radiation, but high pulsed frequency.

Using the device is simple because it has been designed so that it can meet ambulatory usage and can be mounted and applied by the patient himself. Its small size and weight that makes it easy to handle.

The device should be applied to the skin, near the fracture site, without the possibility of affecting a nearby metal implant. It can also be used in plaster cast immobilized fractures, as it gives the possibility of applying the ultrasound emitter electrode through a small “window” at the bottom of the immobilized section.

The parts of cold ultrasound device(fig.no.2):

- 1) Device itself
- 2) Ultrasound electrode
- 3) Direction device for the ultrasound transmitter head
- 4) Cloth pad to protect the skin
- 5) Special gel that helps transmission of ultrasounds at the level of the skin



Fig. no. 2 The parts of cold ultrasound device

The technique of using device is a simple one and includes the following steps (figure no. 3):

1. marking on the skin the place where we will apply the device;
2. bracket bonding pad on the bottom of the ultrasound transmitter guiding device;
3. closely guiding device application on the skin, with fastening tape;
4. application of gel on ultrasounds transmitter;
5. placing of ultrasounds transmitter through the guide ring;
6. ensuring intimate contact skin - ultrasounds transmitter

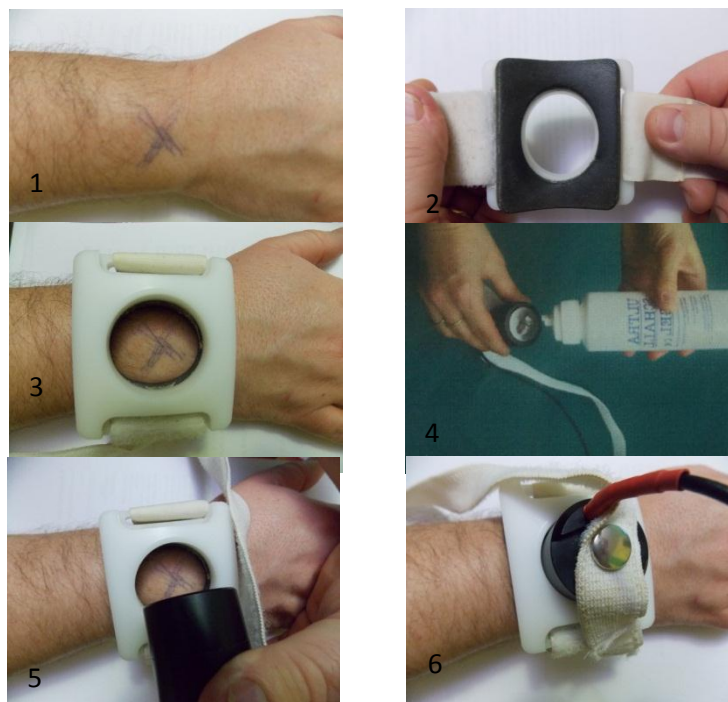


Fig. no. 3 The technique of using the ultrasound device

Each patient in the study has used the ultrasounds device over a period of 60 days, 20 minutes daily, the time of the therapy session being indicated acoustically and visually on the screen of the device. Non-unions were considered to be healed if they met the clinical (no pain in mobilization or weight bearing, possibility of weight bearing without help, absence of functional impairment) and radiological criteria (presence of callus bridging on at least 3 of 4 cortices on the radiographs made in two incidents: anterior-posterior and lateral).

VI.3 Research results

Between 2009-2012, 12 patients diagnosed with non-union or late bone consolidation have been treated with cold ultrasound, and all subjects of the study met the inclusion and exclusion criteria presented in the previous section of this paper.

To establish a diagnosis three parameters were used:

1. clinical elements:

- a. pain on the fracture site;
- b. functional impotence of the affected limb;
- c. pathological mobility at the fracture site;
- d. deformity of the limb;
- e. inability to walk without aid (crutch /cane) in case of lower limb fractures.

2. radiological examinations (minimum two ortoroentgengrade incidents)

- a. no callus on radiological images (minimum 3 periosteal or endosteal cortical bridging)

3. average time between the actual accident (fracture moment)and the establishment of diagnosis:

- a. minimum of 3-6 months-delayed union;
- b. over 6 months-pseudoartosis.

Diagnosis certainty was based on association of at least two clinical elements with the radiological aspect, and the period of time between the moment of trauma and the starting day of the stimulation treatment of fracture site consolidation using ultrasounds. Thus, the study includes 6 pseudoartrosis and 6 delay of union cases.

Pain was a common symptom in all studied cases, and in establishing the diagnosis, two other aspects were considered:

- inability to walk without aid (crutch /cane)-8 cases
- functional impotence of the affected limb-4 cases

There has been no case of pathological mobility at the fracture site or deformity of the limb.

Average age of the patients under study was 43, the extreme ages were 21 and 61. In five of the cases the subjects were women and the rest of seven cases were men.

The following is a classification based on the bone affected by non-unions or by delayed union:

- tibia-6 cases;
- femur-2 cases;
- humerus-1 case;
- radius-1 cases;
- cubitus-1 case;
- scaphoid-1 case.

In 4 cases the initial fracture was an open one, three cases of tibia fracture, and one case of open radius fracture. Surgery was performed in all cases, except the scaphoid fracture.

Open reduction and osteosynthesis fracture site was performed in 4 cases, whereas in three open fractures of the tibia, intramedullary nail fixation or external fixation was performed. Thus, in the case of all the subjects (7 patients) of the present research we can identify a post-traumatic or surgically open fracture site.

Average time between trauma and initiation of therapy was 214 days, the minimum duration of was 91 days, and the maximum one 742 days. Ultrasound

therapy started 4 months (115 days) after injury for delayed union cases, and after 10 months(315 days) for pseudoarthrosis cases.

After ultrasound therapy was performed, all patients became subjects of clinical and radiological assessment. In 8 cases (75%) clinical and radiological conditions of fracture consolidation were met. The therapy proved to be successful, and the radiographs showed at least three cortical bones on the two standard incidents. Four cases in which fracture repair/healing non-union failed are mentioned below:

- radius fracture complicated by broken of plate osteosynthesis;
- femoral fracture operated upon with intramedullary locked nail;
- cubitus fracture operated upon with K intramedullary pin;
- open fracture of the tibia, previously stabilized with external fixator, and then, with intramedullary locked nail.

Three of the cases above were delayed consolidation cases, and one was diagnosed with nonunion (open fracture of tibia). Three cases of nonunion after ultrasound therapy, the fracture site was opened either surgically, or after trauma. In case of healed fractures, in two cases the fracture site was surgically opened, and in two cases it was opened post-traumatically.

Lack of healing occurred in the case of patients of different age groups (aged 24,31,60,61), two men and two women.

VI.4 Clinical and Radiological Aspects/Features in studied cases

One case out of all the cases that make the subject of our paper needed special attention

B.C-man, aged 52

Diagnosis: Subtrochanteric femur fracture (fig. no. 4-A)

Initial surgical intervention: open reduction and osteosynthesis with plate and screws (fig. nr. 4-B)

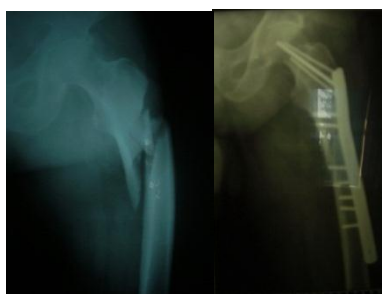

Fig. nr. 4 A – pre-operative radiological aspect;
B – post-operative radiological aspect;

In evolution delayed union occurred and plate showed signs of deterioration, thus another surgical intervention was necessary and extraction of plate and screws, femoral canal reaming and intramedullary nail fixation was performed. This intervention was done 4 months after the initial one.

Unfavourable outcome, proved to be an issue in this case, as nonunion occurred thus, initiation of surgical treatment started and augmented with auto graft bone harvested from the iliac crest and changing the intramedullary rod was proceeded; 5 months after the intervention, there were major signs of fracture nonunion, and ultrasound therapy was initiated, as the following stage of protocol treatment. The outcome was eventually a favourable one, as union at the pseudoarthrosis site was shown on the radiographs.(fig. no.5).

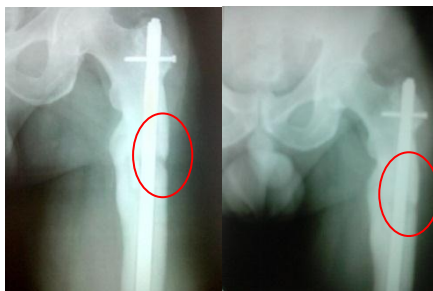

Fig. no. 5 A – pre-ultrasound therapy radiological aspect; B – post-ultrasound therapy radiological aspect;

VI.5 Conclusions

1. Although, from a clinical-radiological point of view, there are no differences between delayed union and pseudoarthrosis, time is the only factor that can make a difference in this situation, because it triggers a different therapeutical attitude.
2. Radiological examination is a must, and it has to be performed and interpreted in connection with the appropriate clinical context, in order to establish a delayed union or a pseudoarthrosis diagnosis.
3. Establishing a delayed union or pseudoarthrosis diagnosis is a very difficult task, as clinical symptoms, that signal pseudoarthrosis (pathological mobility at the fracture site, bone crepitation, interruption of bone continuity, no movement at the fracture site) do not always occur in the case of fractures where osteosynthesis was performed.
4. Age and sex markers were not considered negative prognosis factors in the evolution of fracture towards delayed union or pseudoarthrosis, not before or after ultrasound therapy.
5. Tibia is considered to be the bone that is highly prone to delayed union or pseudoarthrosis, based on its anatomic-structural characteristics, and on the fact that it is the bone that is commonly involved in open fractures. Ultrasound therapy was not influenced by initial localisation of the fracture.
6. The factors that influence the evolution of a fracture towards delayed non-union or pseudoarthrosis are: traumatically or surgically opened fracture (a situation in which deterioration and devascularisation of the bone are associated), anatomical and vascular characteristics of the bone, insufficient or inadequate osteosynthesis, infection at the fracture site.
7. Equal proportion of union/nonunion of the fractures in which the fracture site was opened (surgically or traumatically), after performing ultrasound therapy, clearly indicates that evolution of the fracture site after ultrasound therapy is

not influenced by initial clinical condition of the fracture or the type of osteosynthesis decided upon.

8. Surgical treatment of pseudoarthrosis is „the golden standard” even if healing stimulation at the fracture site by means of ultrasound therapy fails.
9. Ultrasound therapy has proved to be successful even for failure of surgical treatment of femoral pseudoarthrosis.

CHAPTER VII

THE INFLUENCE OF ULTRASOUND THERAPY IN THE EVOLUTION OF OPEN TIBIAL SHAFT FRACTURES

VII.1 Introduction to the research

Over the time, low frequency pulsed ultrasounds have been successfully used in the treatment of delayed union, or even pseudoarthrosis. Mechanism that makes these ultrasounds stimulate the process of bone healing, still remains a mystery, although there are some theories that highlight the idea that ultrasounds trigger a micro-mechanical stress that accelerate cellular metabolism.

VII.2 The purpose of the research

Perfectly aware of the pathophysiology of open fractures, and of the fact that one of the most important stage for a favourable evolution-fracture hematoma stage-is missing, the purpose of the present paper is to determine whether low frequency pulsed ultrasounds may have a positive influence or even shorten the healing period in open tibial shaft fractures..

VII.3 Materials and methods used during the research

The present study focuses on open tibia shaft fractures operated in the Clinical Department Of Orthopaedics and Traumatology ,Emergency County Hospital of Sibiu between 2010-2012.The study does not include all patients who presented open tibia shaft fractures, because a selection based on inclusion-exclusion criteria was used, in order to get a solid study group, with similar characteristics ,as far as fracture and influential factors in the normal course in fracture evolution are concerned.

Study inclusion criteria was:

- open tibia shaft fractures;
- open tibia shaft fractures(type I,II,IIA-Gustilo-Anderson classification);
- fractures treated with locked reamed intramedullary nail osteosynthesis;
- aged over 18,or emphasizing closure of a growth plate epiphysis.

Study exclusion criteria was:

- Open tibia fracture type IIIB,IIIC(Gustilo-Anderson classification)
- Fracture location/extension in the epiphyseal part (5 cm proximal /distal) of the tibia;
- Bifocal fractures of the tibia;

- A period of time of over 10 days from the moment when the fracture occurred and definitive stabilization;
- Fracture with bone defects needing bone grafting;
- Occuring of an infection at the site of fracture;
- Politraumas;
- Known abuse of alcohol, tobacco or drugs;
- presence of neuropathy, active malignancy or chronic metabolic diseases affecting bone formation;
- treatment with hormones, steroids, anticoagulants or bisphosphonates;

Based on the previously mentioned criteria, a number of 22 patients were included in the research. However, 5 patients were excluded from the study, as 2 of them presented infection at the fracture site, and 3 gave up therapy that included performance of all stages in the observation of evolution, based on objective or personal reasons.

All the other patients in the study group went through all stages of the therapy. Subjects were divided into two groups:

- ✓ group A-patients treated with high frequency pulsed ultrasounds;
- ✓ group B-patients for whom high frequency ultrasound therapy was not applied.

Patients from group A, that were included in the research have agreed with application of cold ultrasound treatment in the case of open tibia fracture, that was clinically and radiologically diagnosed.

Cold ultrasound therapy was performed by means of a portable device, an alternative of the devices that stimulate new bone production, using low intensity ultrasound radiation, but high pulsed frequency.

All patients in group A were given this kind of specialized therapy, in which each patient used the ultrasound device over a period of 60 days, 20 minutes daily, as time was previously pre-set. The time of the therapy session was indicated acoustically and visually. Therapy was initiated 3 days after fracture definitive stabilization, and it took place within the premises of the patient's home, after prior training on the way the device worked.

Continuous assessment of the fracture was performed by strictly set medical checks, that included clinical-radiological evaluation of fracture at 1,2,3,4,5,6 months (within a margin of +/- 5 days), and at 9 and 12 months (within a margin of +/- 14 days). 3,6,9 and 12 months after operation focused on a global assessment of healing at the fracture site, and the 9 and 12 months medical checks radiographs were analysed to see whether the fracture line disappeared.

The criteria upon which evaluation of fracture consolidation were based upon, were divided in two categories, and registered in a chart, at every meeting with the subjects of the present research:

1. clinical criteria:
 - absence of pain at rest or in motion, at the fracture site;
 - absence of mobility at the fracture site;
 - possibility to walk without aid (crutch /cane);
 - no other intervention that might favour callus formation at the fracture site;
2. radiological criteria:

- presence of callus bridging on at least 3 of 4 cortices on the radiographs made in two ortoroentgengrade planes(anterior-posterior and lateral)

In the case when all the previous criteria were met, the fracture was considered to be healed.

Approximation of the moment when cortical bridges might occur, and of fracture healing was calculated in terms of the number of days that passed after surgery.

Data collected in all of the 8 meeting with the patients was introduced in a chart, that included information on local pain evaluation, soft tissue lesions, radiological aspect at the fracture site, and that also measured evolution from one meeting to the other. Gathered data was analysed in order to evaluate outcome.

VII.4 Research findings/results and discussions

Between 2010-2012 in the Clinical Department Of Orthopaedics and Traumatology, Emergency County Hospital of Sibiu 5432 patients have been hospitalized, and a number of 256 patients were diagnosed with fracture of lower leg. Out of this number, 216 patients had closed fractures, and 40 patients had open fractures. However, only 17 patients (8-group A; 9-group B), who presented open fracture of the lower leg, succeeded in meeting the inclusion criteria of the present research.

Average age of the study group was 40 years and 6 months(36 years-group A; 43 years-group B), and the extreme ages 18 and 70 years. The study group included 15 men and 2 women.

Ethiology of open fractures of the lower leg covered a wide range. Crushing accidents were caused by the fall of a wall(1 case), of a log (2 cases), or a metal panel(2 cases). Household accidents were caused by a fall at the same level(3 cases), or a slip on ice(1 case). Traffic accidents included pedestrians(4 cases), and the occupant of a vehicle(1 case).

Assessment of the lesion degree of soft tissue associated with fracture of the lower leg bones, allowed systematisation of fractures based upon Gustilo-Anderson classification(fig.no.6). If distribution of cases for open fractures type I and II maintained an equilibrium in the two groups under study, one can notice that those two open fractures IIIA belonged to group B.

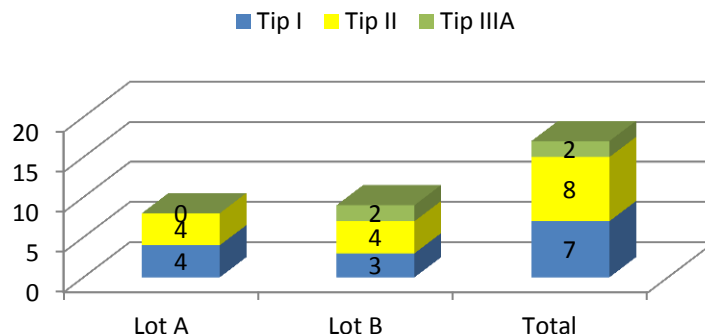


Fig. no. 6 Systematisation of fractures based upon Gustilo-Anderson classification

A systematisation of the cases under study was done based on the complexity of the fracture site, by means of the radiographs performed in the moment of hospitalisation. (fig.7)

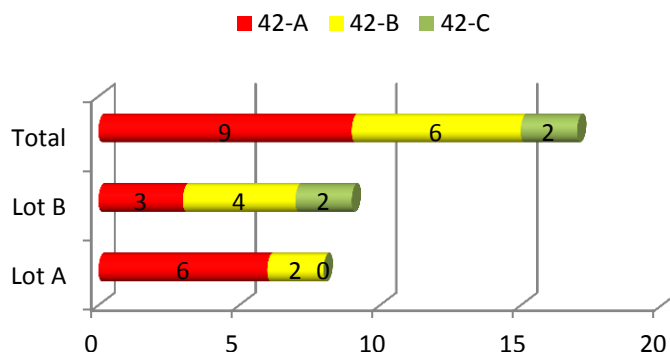


Fig. no. 7 Systematisation of the cases under study based on the complexity of the fracture site.(classification AO_ASIF)

Average number of hospitalisation days was 13,5(7 days minimum,34 days maximum),and the average number of days from the moment of hospitalisation until definitive osteosynthesis was 6 days.(2 days minimum,10 days maximum). Longer periods between moment of hospitalisation and definitive osteosynthesis was due to presence of posttraumatic circulatory disorders, that occurred at the fracture site, sometimes in association with fracture blisters.(fig.8)

Definitive stabilisation of fractures was performed by reamed locked static intramedullary nailing. During the surgery one incident occurred: the drill broke in the attempt to proximally lock the tibia, using the guidelines included in the medical kit.

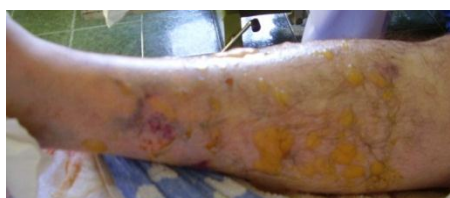

Fig. no. 8 Posttraumatic circulatory disorders (fracture blisters) in open fractures of the lower leg bones

Comparative analysis of the groups under study has shown the following:

- ✓ patients in group A met the clinical criteria of fracture healing earlier with an average of 22 days;
- ✓ healing radiological criteria were met earlier with an average of 60 days in group A;
- ✓ comparative analysis of the studied groups, that was meant to highlight clinical bone healing criteria, has shown that in the situation of the two study groups in 2/3 of the cases the moment in which the criteria were met almost matches;
- ✓ comparative analysis of the studied groups, that was meant to highlight radiological bone healing criteria, has shown that in all cases from group B, they were met with a certain delay.

An important issue in the present research was evolution of the fracture union, based on the lesion degree of soft tissues, that was associated with the open fracture (Gustilo-Anderson classification). This aspect was analysed by measuring union data collected at the fracture site 3,6,9 and 12 months after surgery, for each study group.

All fractures type II healed within 3 months, in both situations of group A and B. A fracture that was considered type I healed within 3 and 6 months, whereas the others healed in the first 3 months. In the case of the fractures type IIIA, one healed after 3 months and the other after 9 months.

The period of time that is needed for fracture healing (measured in terms of days), has shown the fact that, statistically speaking, there are no major differences, and the period of time necessary for fractures type IIIA, doubled-if compared with the other types of fractures that make the purpose of the present study. Although, from a statistical point of view, there were no significant differences of time, as far as healing period is concerned, in the situation of type I and II, earlier union occurred for patients in group A (an average time of 33 days for fractures type I, and an average period of 31 days for type II)

An analysis of the fracture site evolution, based upon the complexity of the fracture(AO classification) has reached the following results:

- ✓ one of the simple site fractures(42A) healed between 3-6 months from surgery, and another one between 6-9 months;
- ✓ fractures type 42B healed in the very first 6 months, the majority (5) healed in the first three months;
- ✓ fractures type 42C needed a longer period to heal;
- ✓ there was a difference of 46 days between group A and group B for fractures 42A, as far as healing period is concerned, and a difference of only 9 days for fractures 42B;
- ✓ a comparison of the difference between the period of time needed for fractures type A and B to heal, and the total time of fracture healing, one can reach the conclusion that it was 5 days shorter, respectively 18 days longer for group A, and 19 days, respectively 33 days shorter for group B-due to an average longer period of time (228,5 days) needed for healing type C fractures, situation that definitively influences the average global time for fracture healing.

In an statistical analysis of fracture healing, as far as its occurrence at the tibial diaphysis level is concerned, the present research has taken into consideration only fractures located in the 1/3 medium and distal of the tibial diaphysis, because there was only one case of a fracture 1/3 proximally located. The results of this analysis are:

- ✓ all fractures in group A healed in the first 3 months after surgery;
- ✓ in one case from group B the fracture, that was 1/3 medium located healed between 6 and 9 months after operation;
- ✓ in two cases from group B, located 1/3 distal of the tibial diaphysis, the fractures healed between 3 and 6 months after surgery;
- ✓ average difference of time in healing fractures from group A was of 15 days, in favour of those 1/3 medium located;
- ✓ average difference of time in healing fractures from group B was of 4 days, in favour of those 1/3 distally located;
- ✓ a comparison of the difference between the period of time needed for fractures to heal based on their anatomical location, and the global healing/consolidation time of fractures, it was 5 days shorter in the case of

fractures located 1/3 medium, respectively, 10 days longer for fractures located 1/3 distal, in group A, and 10 days, respectively, 14 days shorter for group B.

VII.6 Conclusions

1. Anatomical, etiological and pathophysiological characteristics of the lower leg impose in the case of open fractures, differentiated lesion characteristics, multiple clinical aspects, therapeutical issues and doubtful prognosis.
2. Open fractures of the diaphysis of tibia occur in any category of age, but usually, they are considered an ordinary issue for those who live an active life.
3. The most common site for fracture was the distal and medium third (1/3) of the tibia, a situation that can be easily explained by tibia architectural structure, and anatomical features of lower limb area, where tibia is superficially located at the skin surface, and receives less protection, due to the soft tissue from this level.
4. Increased number of open fractures of the lower limb is due to road traffic and workplace accidents.
5. In the case of road traffic, pedestrians are more prone to suffer from open fractures of the lower leg.
6. Open fractures of lower limb caused by car accidents, crush injuries, falls from height are characteristic for the active period of one's life, whereas, open fractures of lower limb caused by household accidents are characteristic for the category of age over 50. This highlights the fact that open fractures mostly occur in active lives, whereas, for people of over 50, opening of the fracture site was caused by „in-out mechanism”, a favourable element, as far as prognostic terms are concerned.
7. Lesion degree of soft part tissues and bone structures is proportional to the traumatic mechanism type and kinetic energy level produced by this, a fact that definitively influences further development of fracture healing. However, the utmost outcome, in the treatment of open fractures, that is satisfactory functional recovery, is not an easy target to achieve.
8. Complexity of the fracture site is an important element as far as intensity traumatic approach is concerned. Comminuted fractures, usually involve complex lesions in surrounding soft tissue, and both of them may have a negative influence upon natural evolution of fracture healing.
9. Treatment of open fractures of lower limb, is a process that involves several stages, and follows a well-defined therapeutic algorithm, as far as soft part tissues and osteosynthesis of the fracture site is concerned.
10. Long average hospitalisation period is due to the fact that definitive osteosynthesis of the fracture site was initiated after remission or improvement of local post traumatic disorders. Thus, hospitalisation costs, in the case of open fractures, are above the average.
11. Absence of local pain, in most of the cases under study, involves movement at the fracture site, and impossibility to walk without aid (crutch /cane), in most of the cases, were consequences of the type of osteosynthesis applied -reamed locked intramedullary nailing. Number of cortical bridges, that are in favour of patients in group A, the group that was subjected to cold ultrasound treatment of the fracture site, highlight the positive aspect of this type of treatment.

12. Favourable difference of patients, with an advantage of group A, after two months from the surgery revealed first healing signs on radiographs, besides improvement of clinical consolidation criteria.
13. Clinical-radiological healing can be noticed in the case of all patients in group A (the radiographs showed the presence of four cortical bridges, in some of the cases), whereas in group B some of the patients showed no signs of cortical bridges at the fracture site.
14. Patients in group A showed no complications at the fracture site, union occurred early in all cases, with an average period of time of 22 days faster than in group B in which one of the patients delayed union at the fracture site was revealed.
15. All consolidation criteria were met earlier, in both groups A and B, due to the type of osteosynthesis performed.
16. Clinical consolidation criteria occurred earlier in group A, if compared to group B, although in 2/3 of the cases the moment of clinical union of the fracture was very close from one another.
17. Radiological criteria of union at the fracture site occurred later than the clinical criteria, in the situation of both groups, with a slight difference, in favour of group A.
18. Radiological criteria that showed union at the fracture site, needed a longer time, twice as long, in group B, after all clinical criteria were met.
19. As clinical criteria were met earlier, due to the strict osteosynthesis of the fracture site that was performed and to the appropriate therapy of soft tissues, a fact that the idea that evolution of the fracture showed on the radiographs is the major signal of fracture consolidation.
20. There are no significant differences between union time in the case of fractures type I and II (Gustilo-Anderson classification), although significant differences between the two groups show that fracture union occurred earlier in group A.
21. Healing period, that is almost twice in terms of length for open fractures type IIIA, if compared to type I and II, highlight the prognostic importance of application of Gustilo-Anderson classification, that is mostly used in this situation.
22. As far as open fractures are concerned, complexity of the fracture site cannot be used as an appropriate indicator of prognosis in the evolution of fracture consolidation; thus, Gustilo-Anderson classification is used in this situation.
23. Early union of fractures in group A, localised in the medium third(1/3)of the tibia, an area that is very well vascularized, supports its role in the pathophysiology of fracture healing and accelerates cell metabolism theory, by means of pulsed high frequency ultrasounds, used at the fracture site.
24. Adjunctive pulsed high frequency ultrasound therapy involves no contraindications, and did not determine any local, or general complications.
25. Final results holds a reference position in adjunctive therapy of open fractures, situations in which late complications, such as delayed union or pseudoarthrosis may frequently occur.

CHAPTER VIII

C-T SCANNING UTILITY IN FOLLOWING AND ASSESSMENT OF OPEN FRACTURES OF THE TIBIAL DIAPHYSIS

VIII.1 Introduction

Standard observation of the evolution of a fracture is based on local clinical features and radiological images in at least two views. The other imaging technologies, such as magnetic resonance imaging, computed tomography, bone scintigraphy are not considered a routine in exploration of the fracture site, because they prove to be useful especially in soft part tissues disorders (magnetic resonance), tumoral pathology (computed tomography and bone scintigraphy). CT and MRI examinations have proved to be especially useful in traumatology of the spine, pelvis and articular fractures of long bones. In the situations mentioned above, imaging technologies are used to establish a clear diagnosis, a realistic prognosis, and appropriate therapy planning. Seldom, CT examination is used in those situations in which radiological examination of the fracture cannot give sufficient data to achieve the utmost result, that is union.

VIII.2 Purpose of the Research

Perfectly aware of the slow process of evolution of diaphyseal open fractures of lower limb, the purpose of the present research is to evaluate the importance and the possible advantages of the observation of the fracture site healing process, by means of CT scanning. Obtained data are interpreted and compared to data gathered from observation of radiological examination of the fracture site.

VIII.3 Materials and Methods used During the Research

The present research has focused on cases of open fractures of the tibia between 2010-2012 in the Clinical Department Of Orthopaedics and Traumatology ,Emergency County Hospital of Sibiu. The study does not include all patients with tibia open fractures, because the research is based on a series of inclusion and exclusion criteria, in order to get a compact study group, with similar characteristics, as far as fracture and influential factors in a normal evolution are concerned.

Study inclusion criteria, the present research is based upon:

- open tibia shaft fractures;
- open tibia shaft fractures (type I,II,IIIA - Gustilo-Anderson classification);
- fractures treated with locked reamed intramedullary nail fixation;
- patients aged over 18, or emphasizing closure of a growth plate epiphysis;

Study exclusion criteria, the present research is based upon:

- Open tibia fracture type IIIB,IIIC(Gustilo-Anderson classification)
- Fracture location / extension in the epiphyseal part (5 cm proximal / distal) of the tibia;
- Bifocal fractures of the tibia;

- Fracture with bone defects needing bone grafting;
- Politraumas;
- presence of neuropathy, active malignancy or chronic metabolic diseases affecting bone formation.

Selection based upon the previously mentioned criteria, included a number of 6 patients.

Intervention was performed by a single orthopaedic surgeon, and the same osteosynthesis method was used: reamed locked intramedullary nailing.

Clinical, radiological, and CT examination was performed in the case of every patient 1,3,6,and 12 months after surgery.

Clinical evaluation of the fracture site focused on identifying elements that stand for evaluation of clinical union of the fracture site ,too:

- ✓ local pain;
- ✓ motion at the fracture site;
- ✓ possibility to walk , without aid(crutch /cane),and weight-bearing ability on the operated foot/ limb;

Radiological criteria that highlighted union at the fracture site was:

- ✓ presence of 3 cortical bridges (endosteal and periosteal aspects) in two views.

Fracture was considered to be healed, from a clinical-radiological aspect, when it met all clinical and radiological criteria mentioned above.

CT examinations provided images in axial plane (fig.no.9),and 2D reconstructions were performed in in coronal and sagittal planes. For the coronal reconstruction (fig.no. 10), the "slices" are located parallel to a tangent line to the rear edge of the tibial condyles. In the sagittal reconstruction, the "slices" are located perpendicular to a line tangent to the tibial plateau. Images collected show the entire fracture site and 2 extra cm below and above it.

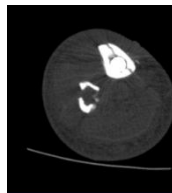


Fig. nr. 9 CT image in axial plane

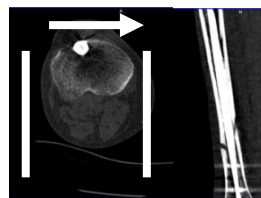


Fig. nr.10 CT reconstruction in sagittal plane

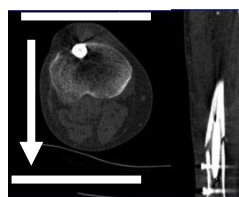


Fig. nr.11 CT reconstruction in coronal plane

Clinical, radiological, and computed-tomography data collected during every medical meeting, that was carefully planned in the case of every patient, were registered, by means of a fill in form.

VIII.4 Results and Discussions

Average age of the study group was 45 years, the extreme ages were 19, and 65. According to Gustilo-Anderson classification, the research includes two open fractures for each type I, II and IIIA. Using radiographs performed in the moment of admission (anterior-posterior and profile view), another classification of the cases was realised, based on the complexity of the fracture site (AO classification). Thus, there were two type A, two type B and two type C fractures. Injury mechanism was a direct one (crush fracture), in 4 cases, and an indirect one, in two of the cases (falling from height - 1 case; fall from the same level - 1 case).

Fractures under study were located in the middle 1/3 (3 cases), and in the distal 1/3 (3 cases) of the tibial diaphysis, in association to fibula fracture, at different levels. In all cases, debridement, sterilisation, and primary suture of the wound was performed at the fracture site.

Average hospitalisation period was 16,5 days, with a minimum of 12 days, and a maximum of 34 days (a fracture complicated by skin necrosis). Hospitalisation period was double in the case of open fractures type IIIA (27 days), if compared to open fractures type I (15 days). Average time between hospitalisation period and definitive stabilisation of the fracture site was of 8 days, with a minimum of 4 days, and a maximum of 13 days. This situation doubled its sizes, as it was approximately 2,5 bigger (11 days) in the case of open fractures type IIIA, than in the case of open fractures type I (4,5 days).

One month after surgery (table no.5), most of the patients showed no signs of pain at the fracture site, 5 were able to walk without a cane, and 3 patients showed the presence of cortical bridges on the radiographs. An analysis of the CT images showed the presence of two cortical bridges in the case of 3 patients. None of the fractures met the clinical-radiological criteria, in this evolution stage.

Table no. 5 Evaluation of healing process at the fracture site one month after surgery

Pain		Yes	No		
	At rest	2	4		
	During mobilisation	1	5		
Motion at the fracture site		4	2		
Possibility to walk without cane/crutch		1	5		
Cortical bridges visible on the radiographs	0	1	2	3	4
	3	3	0	0	0
Cortical bridges visible on CT	0	1	2	3	4
	2	1	3	0	0

Three months after surgical intervention, all patients –subjects of the present research, met the clinical healing criteria at the fracture site, and two of them met the radiological healing criteria (table no. 6). The same situation stands at one months ,

after surgical intervention, when CT examination of the fracture site showed evidence of more cortical bridges than the ones showed on the radiographs. According to the CT examination, in the case of 3 patients at least 3 cortical bridges between the fractured bone fragments. To conclude, three months after surgical intervention, only two cases met the clinical-radiological healing criteria.

Table no.6 Evaluation of healing process at the fracture site three months after surgery

Pain		Yes	No		
	At rest	0	0		
	During mobilisation	0	0		
Motion at the fracture site		0	0		
Possibility to walk without cane/crutch		6	0		
Cortical bridges visible on the radiographs	0	1	2	3	4
	1	2	1	1	1
Cortical bridges visible on CT	0	1	2	3	4
	1	1	1	2	1

Six months after the surgical intervention, the clinical-radiological analysis showed that clinical healing criteria at the fracture site were met by all patients, and 5 of them met the radiological criteria. It is important to mention that both radiologically and at on CT examination the same number of cortical bridges between the fractured fragments were evident.(table no.7) In the case of the patient that did not meet the radiological consolidation criteria, a new diagnosis was established-delayed union.

Table no.7 Evaluation of healing process at the fracture site six months after surgery

Pain		Yes	No		
	At rest	0	0		
	During mobilisation	0	0		
Motion at the fracture site			0		
Possibility to walk without cane/crutch			0		
Cortical bridges visible on the radiographs	0	1	2	3	4
	1	2	1	1	1
Cortical bridges visible on CT	0	1	2	3	4
	1	1	1	2	1

Twelve months after surgical intervention, all patients met the clinical-radiological criteria of healing of the tibial fracture site. In addition, radiological and CT examination showed evidence of the same number of cortical bridges between the fractured tibial bone fragments (table no. 8)

Table no. 8 Evaluation of healing process at the fracture site twelve months after surgery

Pain	Yes		No		
	At rest	0	0	0	0
During mobilisation	0	0	0	0	
Motion at the fracture site	0	0	0	0	
Possibility to walk without cane/crutch	6	0	0	0	
Cortical bridges visible on the radiographs	0	1	2	3	4
	0	0	0	2	4
Cortical bridges visible on CT	0	1	2	3	4
	0	0	0	2	4

VIII.5 Conclusions

1. Open fractures of diaphyseal tibia may be met in any category of age , but are specific to an active lifestyle.
2. Lesion complexity and of the fracture site is closely connected with the kinetic energy developed by the traumatic agent that causes the fracture.
3. Localisation of open fracture at the middle and distal third of the tibia may be easily explained by the architectural structure, and the anatomical features of the lower limb area, where tibia is superficially located at the skin surface, and receives less protection, due to the soft tissue from this level.
4. Treatment of open fractures of lower limb, is a process that involves several stages, and follows a well-defined therapeutic algorithm, as far as soft part tissues and osteosynthesis of the fracture site is concerned.
5. Long average hospitalisation period is due to the fact that definitive osteosynthesis of the fracture site was initiated after remission or improvement of local post traumatic disorders. Thus, hospitalisation costs, in the case of open fractures, are above the average.
6. Clinical healing criteria of the fracture site are met earlier than radiological criteria, due to the strong osteosynthesis performed at the lower limb level.
7. Conservative therapeutic approach is an useful option in delayed union situations, that met all clinical criteria.
8. CT examination frequently showed less cortical bridges between the fractured bone fragments, in the very first months after surgical intervention, but later on, the radiological and CT results were identical. Thus, a conclusion can be drawn in the case of CT examination, that is a valuable „tool”,with a predictive value in the evolution of the fracture site, or in borderline cases of consolidation of the fracture site.
9. Results of the present research in conjunction with high costs and high irradiation, highlight the fact that CT examination is an inappropriate investigation in the routine observation of the evolution of healing of the fracture site in cases of open fractures of lower limbs.

REFERENCES

1. Alexa O., Stratan L., Cionca D.: valoarea antibiograamei în fracturile deschise, Conferința Națională de Ortopedie și Traumatologie, Timișoara, 21-23 octombrie, 1998;
2. Altman GH Horan RL, Martin I, et al. Cell differentiation by mechanical stress. *FASEB J.* 2002 16(2):270-272;
3. Andreassen T.T., Fledelius C., Ejersted C., Oxlund H.: Increases in callus formation and mechanical strength of healing fractures in old rats treated with parathyroid hormone, *Acta Orthop. Scand.*, June 2001, 72(3): 304-307;
4. Andrew J.G., Hoyland J.A., Freemont A.J. et al.: Platelet derived growth factor expression in normally healing human fractures: *Bone*, 1995, 16(4):455-460;
5. Angele P, Zoo JU, Smith C, et al. Cyclic hydrostatic pressure enhances the chondrogenic phenotype of human mesenchymal progenitor cells differentiated in vitro. *J Orthop Res.* 2003 21(3):451-457;
6. Antonescu Dinu M. Fracturile. Generalități., în *Patologia Aparatului Locomotor*, sub redacția Dinu M. Antonescu, Ed. Medicală București, 2006, 243-287;
7. Arden NI Jr, Janes JM, Herrick JF. Ultrasonic energy and defects in bone. *J Bone Joint Surg Am* 1957;39:394-402;
8. Aronson J., Rock L.: Limb-Lengthening, Skeletal Reconstruction and Bone Transport with the Ilizarov Method, *J.B.J.S.*, Vol. 79-A, No.8, August 1997, 1243-1255;
9. Ashford R.U., Garcia A.F., Patel K.K., Campbell P.:Delays in Open Fractures Management: Where Do They Occur?, *injury*, 2004 Nov, 35(11): 1077-1218
10. Barnes GL, Kostenuik LC, Gerstenfeld LC, et al. Growth factor regulation of fracture repair. *J Bone Miner Res.* 1999 14:1805-1815;
11. Bassett Cal., Mitchell S.N., Gastron S.R.: Treatment of ununited tibial diaphyseal fractures with pulsing electromagnetic fields, *J. Bone and Joint Surg.*, 1981, 63A: 511-523;
12. Bhandari M, Guyatt GH, Tong D, Adili A, Shaughnessy SG. Reamed versus nonreamed intramedullary nailing of lower extremity long bone fractures: a systematic overview and meta-analysis. *J Orthop Trauma* 2000;14:2-9;
13. Binder S.M., Rubins I.M., Desjardin J.V., Zukor D.J., Goltzman D.: Evidence for a humoral mechanism for enhanced osteogenesis after head injury, *J. Bone and Joint Surg.*, sept. 1990, 72-A:1144-1149;
14. Bohner M., Calcium orthophosphates in medicine: from ceramics to calcium phosphate cements, *Injury*, 2000, 31:D37-47;
15. Bone L.B., Johnson K.D.: Treatment of tibial fractures by reaming and intramedullary nailing. *J. Bone and Joint Surg.*, 68-A: 877-887, July 1986
16. Boni T. Changes in the concept of the fracture healing and callus formation, *Orthopade* 2000 Dec., 29(12):1072-81;
17. Bostrom M.P., Expression of Bone Morphogenetic Proteins in Fracture Healing. *Clin Orthop.* 1995 321: 223-234;
18. Bostrom MP. Expression of Bone Morphogenetic Proteins in Fracture Healing. *Clin Orthop.* 1998 355:116-123;
19. Brighton C, The Biology of Fracture Repair. *Instruct. Course Lect.* 33:60-82, 1984;
20. Bucholz R.W., Carton A., Holmes R.E.: Hydroxyapatite and tricalcium phosphat bone graft substitutes. *Orthop Clin North Am.*, 1987 18:323-334;

21. Buckwalter JA, Glimcher MJ, Cooper RR, Recker R.: Bone Biology. Part I, JBJS, Vol. 77-A, No. 8, August 1995, 1256-1275;
22. Buckwalter JA, Glimcher MJ, Cooper RR, Recker R.: Bone Biology. Part I, JBJS, Vol. 77-A, No. 8, August 1995, 1256-1275; Giannoudis P.V., Einhorn T.A., Marsh D.: Fracture Healing: The Diamond Concept, Z. Orthop. Unfall., 2008, sep-oct, 146(5):580-585;
23. Buckwalter JA, Glimcher MJ, Cooper RR, Recker R. Bone Biology. Part II, JBJS, Vol. 77A, No. 8, August 1995, 1276-1289;
24. Buxton P., Edwards C., Archer C. Et al.: Growth/differentiation factor-5 (GDF-5) and skeletal development, J.B.J.S. Am., 2001, 83-A suppl 1;
25. Campbell W.C.: The Autogenous Bone Graft, J.B.J.S., 1939, 21, 694
26. Canalis E. Effect of insulin-like growth factor I on DNA and proteins synthesis in cultured rat calvaria. J Clin Invest. 1980 66:709-71;
27. Canalis E., McCarthy T.L., Centrella M.: Effects of platelet-derived growth factor on bone formation in vitro. J. Cell Physiol., 1989 140(3): 530-537;
28. Canalis E.: Effect of platelet-derived growth factor on DNA and protein synthesis in cultured rat calvaria. Metabolism, 30(10): 970-975;
29. Carter DR, Beaupré GS, Giori NJ, Helms JA: Mechanobiology of skeletal regeneration, *Clin Orthop* 355S:S41, 1998;
30. Ceck T., Stoica C., Bratu D., Moculescu C., Ionașcu S.: Grefa liberă de peroneu în corectarea defectelor osoase ale membrului superior, 11th Sorot National Congress of Orthopedics and Traumatology, 19-21 Oct. 2005, 172;
31. Chabra A., Zijerdi D., Zhang J. et al.: BMP-14 deficiency inhibits long bones fracture healing: a biochemical, histologic and radiographic assessment; J. Orthop Trauma, 2005, 19(9);
32. Chapman MW. The effect of reamed and nonreamed intramedullary nailing on fracture healing. *Clin Orthop* 1998;355(Suppl):S230-238;
33. Cheifetz S., Li I.W., McCulloch C.A., et al.: Influence of osteogenic protein-1 (OP-1) and transforming growth factor-beta 1 on bone formation in vitro; Connect Tissue Res., 1996, 35(1-4):71-78;
34. Cheng H, Jiang W, Phillips FM, et al. Osteogenic activity of the fourteen types of human bone morphogenetic proteins (BMPs). J Bone Joint Surg (Am). 2003 85(8): 1544-1552;
35. [Chien-Hung Lai](#), [Chiung-Cheng Chuang](#), [Jimmy Kuan-Jung Li](#), [Shih-Ching Chen](#), [Walter Hong-Shong Chang](#): Effects of Ultrasound on Osteotomy Healing in a Rabbit Fracture Model, *Ultrasound in Medicine and Biology*, [Volume 37, Issue 10](#), Pages 1635-1643, October 2011;
36. Cho TJ, Gerstenfeld LC, Einhorn TA. Differential temporal expression of members of the transforming growth factor beta superfamily during murine fracture healing. J Bone Miner Res. 2002 17:513-520;
37. Claes L., Eckert-Hubner K., Augat P.: The effect of mechanical stability on local vascularization and tissue deformation in callus healing, J. Orthop. Res., Sep. 2002, 20(5): 1099-2005;
38. Claes LE, Heigele CA, Neidlinger-Wilke C, et al. Effects of mechanical factors on the fracture healing process. Clin Orthop Res. 1998 355 Suppl:S132-S147
39. Claes LE, Heigele CA, Neidlinger-Wilke C, et al. Effects of mechanical factors on the fracture healing process. Clin Orthop Res. 1998 355 Suppl:S132-S147;
40. Clemens M.W., Parikh P., Hall M.M., Attinger C.E.: External fixators as an adjunct to wound healing, Plast. Reconstr. Surg. 2008 Apr., 121(4):1-7 ;

41. Connor JM, Evans DA, Fibrodysplasia ossificans progressiva. The clinical features and natural history of 34 patients. *J Bone Joint Surg (Br)*. 1992 64(1):76-83;
42. Connor JM, Evans DA, Fibrodysplasia ossificans progressiva. The clinical features and natural history of 34 patients. *J Bone Joint Surg (Br)*. 1992 64(1):76-83;
43. Constantz B.R., Ison I.C., Fulmer M.T., et al.: Skeletal Repair by in situ Formation of the Mineral Phase of Bone, *Science*, 1995, 267:1796-1799
44. Court-Brown C.M., Keating J.F. and McQueen M.M.: Infection after intramedullary nailing of the tibia. Incidence and protocol for management, *J Bone Joint Surg Br*, Sep 1992; 74-B: 770 – 774;
45. Court-Brown C.M., McQueen M.M., Quaba A.A. and Christie J.: Locked intramedullary nailing of open tibial fractures *J Bone Joint Surg Br*, Nov 1991; 73-B: 959 – 964;
46. Crowley D.J., Kanakaris N.K., Giannoudis P.V.: Debridement and wound closure of open fractures: the impact of the time factor on infection rates, *J Bone Joint Surg Am*. 2006 Dec., 88(12):2739-2748;
47. De Bari C., Dell'Accio F., Vanlauwe J. Et al.: Mesenchymal multipotency of adult human periosteal cells demonstrated by single-cell lineage analysis, *Arthritis Rheum*. 2006, 54:1209-1221;
48. De Bari C., Dell'Accio F., Vanlauwe J. Et al.: Multipotent mesenchymal stem cells from adult human synovial membrane *Arthritis Rheum*. 2001, 44:1928-1942;
49. De Nunno R. L'azione degli ultrasuoni sulla formazione del callo osseo (ricerche sperimentali). *Ann Ital Chir* 1952;29:211-20;
50. Deckers MM, van Bezooijen RL, van der Horst G, et al. Bone morphogenetic protein-3 is a negative regulator of bone density. *Nat Genet*. 2001 27(1):76-83
51. Dellinger E.P., Caplan Ellis, Weaver L.D., Wetz Margaret, Droppert Beth, Hoyt Nancy, Brumback R., Burgess A., Poka A., Bernirschke S.K., Lennard S.E., Lou Mary Ann: Duration of Preventive Antibiotic Administration for Open Extremity Fractures, *Arch. Surg*. 1988, 128(3):333-339;
52. Dellinger E.P., Miller S.D., Wetz Margaret; Grypma Martin, Droppert Beth, Anderson P.A.: Risk of Infection after Open Fractures of the Arm or Leg, *Arch. Surg* 1988; 128(11):1320-1327;
53. Den Boer F.C., Bramer J.A., Blokhuis T.J., et al.: Effect of human recombinant osteogenic protein-1 on the healing of a freshly closed diaphyseal fracture; *Bone*, 2002, 31(1):158-164;
54. Diara A., Rughini L., Merlo G.: Trattamento della fracture di tibia con chiodi di Ender ed ortesi funzionali, *Giornale Italiane di Ortopedia e Traumatologia*, Giugno 1988, Voi. XIV, Fascicolo 2:225-230;
55. Dreesmann H. Uber Knochenplombierung. *Beitr Klin Chir*. 1892, 9:804-810;
56. Edwards R.B., Seeherman H.J., Bogdanske J.J., Devitt Jenifer, Vanderby R.Jr., Markel M.D.: Percutaneous injection of recombinant human bone morphogenetic protein-2 in a calcium phosphate paste accelerates healing of canine tibial osteotomy, *J.B.J.S.*, 2004, 86-A(7);
57. Einhorn T.A., Majeska R.J., Mohaideen A. et al.: A single percutaneous injection of recombinant human bone morphogenetic protein-2 accelerates fracture repair. *J Bone Joint surg Am*. 2003, 85-A(8): 1425-1435;

58. Einhorn T.A.: Enhancement of Fracture-Healing. *J. Bone and Joint Surg.*, 77-A: 940-956, June 1995;
59. Einhorn TA, Majeska RJ, Rush EB, et al. The expression of cytokine activity by fracture callus. *J Bone Miner Res.* 1995 10:1272-1281;
60. Einhorn TA: Enhancement of fracture healing, *Instr Course Lect* 45:401, 1996
61. Emami A, Larsson A, Petrén-Mallmin M, Larsson S. Serum bone markers after intramedullary fixed tibial fractures. *Clin Orthop* 1999;368:220-229;
62. Emami A, Petrén-Mallmin M, Larsson S. No effect of low-intensity ultrasound on healing time of intramedullary fixed tibial fractures. *J Orthop Trauma* 1999;13:252-257;
63. Ferrara N, Davis-Smyth T. The biology of vascular endothelial growth factor . *Endocrine Rev.* 1997 18:4-25;
64. Firică A., Popescu R., Scarlet M., Dimitriu M., Ionescu V., Protopopescu C., Buga M., Constantinescu I., Iliescu N.: L`osteosynthese stable elastique, nouveau concept biomecanique – etude experimentale, *Rev. Chir. Orthop.*, 1981, 67:82-91;
65. Flatley T.J., Lynch K.L., Benson M.: Tissue response to implants of calcium phosphate ceramics in the rabbit spine. *Clin Orthop*, 1983, 179:246-252;
66. Fox S.W., Lovibond A.C.: Current insights into the role of transforming growth factor-beta in bone resorption; *Mol Cell Endocrinol.* 2005 243(1-2):19-26;
67. Frayssinet P., Gineste L., Conte P., et al.: Short-term implantation effects of a DCPD-based calcium phosphate cement. *Biomaterials.* 1998, 19(11-12): 971-977;
68. Friedlaender G.E., Perry C.R., Cole J.D., et al.; Osteogenic protein-1 in the treatment of tibial nonunions, *J.B.J.S Am.*, 2001 83-A Suppl;
69. Fuji M, Takeda M, Imamura T, et al. Role of bone morphogenetic protein type I receptors and Smad proteins în diferențierea osteoblastelor și condroblastelor. *Mol Biol Cell.* 1999 10: 3801-3813;
70. Geiger F., Bertram H., Berger I. et al.: Vascular endothelial growth factor gene-activated matrix (VEGF165-GAM) enhances osteogenesis and angiogenesis in large segmental bone defects. *J Bone Miner Res.*, 2005 20(11): 2028-2035;
71. Gerber H.P., Vu T.H., Ryan A.M. et al.: VEGF couples hypertrophic cartilage remodeling, ossification and angiogenesis during endochondral bone formation. *Nat Med.*, 1999, 5(6): 623-628;
72. Gerstenfeld LC, Cho TJ, Kon T, et al. Impaired fracture healing in the absence of TNF- α signalling: the role of TNF- α in endochondral bone resorption. *J Bone Miner Res.* 2003 18:1584-1592;
73. Gerstenfeld LC, Cullinane DM, Barnes GL, et al. Fracture healing as a post-natal developmental process: molecular, spatial and temporal aspects of its regulation. *J Cell Biochem.* 2003 88:873-884;
74. Giannoudis P.V., Papakostidis C., Roberts C.: A review of the management of the open fractures of the tibia and femur, *JBJS Br.* 2006 Mar., 88(3): 351-357;
75. Giannoudis P.V., Pountos I., Tissue regeneration. The past, the present and the future. *Injury.* 2005 36 Suppl 4: S2-5;
76. Gille J., Dorn B., Bruns J., Behrens P.: Bone substitutes as carriers for transforming growth factor β 1 (TGF β 1) *SICOT* 2002, 26:203-206;
77. Gimble J., Guilak F.: Adipose-derived adult stem cells: isolation, characterization and differentiation potential. *Cytotherapy.* 2003, 5:362-369;

78. Glowacki J., Jasty M., Goldring S.: Comparison of Multinucleated Cells Elicited in Rats by Particulate Bone, Polyethylene or Polymethylmethacrylate; *JBMR*, 1986 1:327;
79. Goodman S.B., Song Y., Chun L., Regula D., Aspenberg P.: Effects of TFG β on Bone Ingrowth in the Presence of Polyethylene Particles, *J.B.J.S.*, November 1999, 81-B(6): 1069-1070;
80. Goodship AE, Cunningham JL, Kenwright J., Strain rate and timing of stimulation in mechanical modulation of fracture healing. *Clin Orthop Res*. 1998 355 Suppl:S105-S115;
81. Gopal S., Majumder S., Batchelor A.G., Knight S.L., De Boer P., Smith R.M.: Fix and flap:the radical orthopedic and plastic treatment of severe open fractures of the tibia, *Plast. Reconstr. Surg*. 2008 Dec., 122(6): 1796-1805;
82. Goransson H, Vuola J, Linden M, Patiala H, Rokkanen P. Filling the bone defect with osteogenic material. An experimental study, *Arch Orthop. Trauma Surg* 1995, 114(3):172-178;
83. Gorun N., Troianescu O.:Fractura deschisă, Ed. Medicală, București, 1979;
84. Gosselin R.A., Roberts I., Gillespie W.J.: Antibiotics for Preventing Infection in Open Leg Fractures. *Cochrane Database of Systematic Reviews* 2004, Issue 1, Art. No. CD003764;
85. Govender S., Csimma C., Genant H.K. et al.: Recombinant human bone morphogenetic protein-2 for treatment of open tibial fractures: a prospective, controlled, randomized study of four hundred and fifty patients; *J.B.J.S Am*, 2002, 84-A(12);
86. Groeneveld E.H., Burger E.H.: Bone morphogenetic proteins in human bone regeneration; *Eur J Endocrinol*. 2000, 142(1):9-21; Kang Q., Sun M.H., Cheng H. et al: Characterization of the distinct orthotopic bone-forming activity of 14 BMPs using recombinant adenovirus-mediated gene delivery. *Gene Ther.*, 2004, 11(17):1312-1320;
87. Gustilo R.B., Merkow R.L., Templeman D.J.:The management of open fractures *Bone Joint Surg. Am.*, 1990, feb, 72(2): 299-304;
88. Gustilo RB, Anderson JT (1976) Prevention of infection in the treatment of one thousand and twenty-five open fractures of long bones: retrospective and prospective analyses. *J Bone Joint Surg [Am]*;58 (4):453–458;
89. Gustilo RN, Mendoza RM, Williams DN (1984) Problems in the management of type III (severe) open fractures: a new classification of type III open fractures.*J Trauma*; 24 (8):742–746;
90. Hamanishi C., Kawabata T., Yoshii T., Tanaka S.: Bone mineral density changes in distracted callus stimulated by pulsed direct electrical current, *Mar*. 1995, *Clin Orthop.*, 312: 247-252;
91. Hanamura H., Higuchi Y., Nakagawa M., et al.: Solubilization and purification of bone morphogenetic protein (BMP) from Dunn osteosarcoma; *Clin Orthop Relat Res.*, 1980, (153):232-240;
92. Hauser C.J., Adams C.A. Jr., Eachempati S.R.: Council of the Surgical Infection Society: Surgical Infection Society Guideline: Prophylactic antibiotic use in open fractures: an evidence-based guideline, *Curr. Med. Res. Opin*. 2006, 22 suppl. 1: S19-22;
93. Haynesworth S.E., Goshima J., Golberg V.M., Caplan A.I.: Characterization of Cells with Osteogenic Potential from Human Marrow, 1992, *Bone*: 13-81;

94. Heckman J.D., Ryaby J.P., McCabe J., Frey J.J., Kilcoyne R.F.: Acceleration of Tibial fracture-healing By Non-invasive, Low-Intensity Pulsed Ultrasound, *J. Bone and joint Surg.*, Jan 1994, 76-A:26-34;
95. Helfet DL, Howey T, Sanders R, et al. (1990) Limb salvage versus amputation. Preliminary results of the Mangled Extremity Severity Score. *Clin Orthop*;(256):80–86;
96. Hench L.L., Bioactive Bone Substitutes. In: Habal M.B ., Reddi A.H.: Bone Grafts and Bone Grafts Substitutes. Philadelphia: W.B. Saunders, 1992, 263-275;
97. Henley M.B., Chapmann Jr., Agel J., Harvey E.J., Whorton A.M.: Treatment of Type II, IIIA and IIIB Open Fractures of Tibial Shaft: A Comparison of Unreamed Interlocking Intramedullary nails and Half-Pin External Fixator, *JBJS Am.*, 2000, Jun., 82(6):781-788;
98. Hente R., Fuchtmeier B., Schlegel U., et. Al. The influence of cyclic compression and distraction on the healing of experimental tibia fractures. *J Orthop. Res.* 2004 22(4):709-715;
99. Hinz P., Wolf E., Schwesinger G., et al.: A new resorbable bone void filler in trauma: early clinical experience and histologic evaluation. *Orthopedics*, 2000, 25(5): 597-600;
100. Horstmann W.G., Verheyen C.C., Leemans R.: An injectable calcium phosphate cement as a bone-graft substitute in the treatment of displaced lateral tibial plateau fractures. *Injury*, 2003, 34:141-144;
101. Hsieh S.C., Graves D.T.: Pulse application of platelet-derived growth factor enhances formation of a mineralizing matrix while continuous application is inhibitory. *J. Cell Biochem.*, 1998, 69(2):169-180;
102. Huang S.C.: Effect of electrical stimulation on callus maturation during callus distraction in rabbits, *J. Formos Med Assoc.*, Jun., 1997, 96(6): 529-534;
103. Jagodzinski M, Breitbart A, Haasper C, et al. Effects of cyclic compression and perfusion on bone marrow stromal cells in a three-dimensional matrix-bioreactor system. 70th Annual meeting of the German Trauma Society, Berlin, 2006;
104. Jagodzinski M, Breitbart A, Hankemeier S, et al. Influence of fibrin glue on proliferation and differentiation of human bone marrow stromal cells seeded on biologic 3-dimensional matrix. 52nd Annual Meeting of the ORS, Chicago. 2006;
105. Jagodzinski M, Drescher M, Zeichen J, et al. Effects of cyclic longitudinal mechanical strain and dexamethasone on osteogenic differentiation of human bone marrow stromal cells. *Eur Cell Mater.* 2004 16(7): 35-41;
106. Jin M., Franck EH., Quinn TM, et al, Tissue shear deformation stimulates proteoglycan and protein biosynthesis in bovine cartilage explants. *Arch Biochem Biophys.* 2001 395 (1):41-48;
107. Johnson B., Christie Jill: Open Tibial Shaft Fractures: A Review of the Literature, *The Internet Journal of Orthopedic Surgery*, 20008, 9(1);
108. Jones E.A., English A., Kinsey S.E. et al.: Isolation and characterization of bone marrow multipotential mesenchymal progenitor cells, *Arthritis Rheum.* 2002, 46:3349-3360;
109. Karuppasamy K., Hutton M., Porteous M.L., A Novel System for the Irrigation of Open Fractures, *Injury*, 35(10):980-981;

110. Kaspar D, Seidl W, Neidlinger-Wilke C, et al. Dynamic cell stretching increases human osteoblast proliferation and C1CP synthesis but decreases osteocalcin synthesis and alkaline Phosphatase activity. *J Biochem* 2000 33(1):45-51;
111. Kelly C.M, Wilkins R.M., Gitelis S. Et al.: The use of a surgical grade calcium sulfate as a bone graft substitute: results of a multicenter trial. *Clin Orthop Relat Res.*, 2001 382:42-50;
112. Kenwright J., Richardson J.B., Cunningham J.L., White S.H., Goodship A.E., Adams M.A., Magnussen P.A., Newman J.H.: Axial movement and tibial fractures – A controlled randomised trial of treatment, *J. Bone and Joint Surg.*, 1991, 73-B(4): 654-659;
113. Kim C.S., Kim J.I., Kim J et al.: Ectopic bone formation associated with recombinant human bone morphogenetic protein-2 using absorbable collagen sponge and beta tricalcium phosphate as carrier; *Biomaterials*: 2005 26(15): 2501-2507;
114. Kingsley DM. The GF superfamily: New members, new receptors, and new genetic tests of function in different organisms. *Genes Dev.* 1994 8:133-146;
115. Klokkevold P.R., Vandemark L., Kenney E.B. et al.: Osteogenesis enhanced by chitosan (poly-N-acetyl glucosaminoglycan) in vitro. *J. Periodontol.*, 1996 67(11): 1170-1175;
116. Kon T, Cho T, Aizawa T, et al. Expression of Osteoprotegerin, Receptor Activator of NF- κ B ligand (Osteoprotegerin Ligand) and Related Proinflammatory Cytokines During Fracture Healing. *J Bone Miner Res.* 2001 16: 1004-1014;
117. Kopylov P., Runnquist K., Jonsson K., et al.: Norian SRS versus external fixation in redisplaced distal radial fractures. A randomized study in 40 patients. *Acta Orthop Scand.*, 1999, 70:1-5;
118. Kristiansen T.K., Ryaby J.P., McCabe J., Frey J.J., Roe L.R.: Accelerated healing of distal radius fracture with the use of specific low intensity ultrasound. A multicenter, prospective, randomised, double-blind, placebo controlled study, *Am J.B.J.S.*, 1997, 79: 961-973;
119. Kugimiya F., Kawaguchi H., Kamekura S. Et al.: Involvement of endogenous bone morphogenetic protein (BMP) 2 and BMP6 in bone formation; *J Biol. Chem.*, 2005, 280(42):35704-35712;
120. Kujala S., Raatikainen T., Ryhanen J., Kaarela O., Jalovara P.: Composite implant of native bovine bone morphogenetic protein (BMP), collagen carrier and biocoral in the treatment of resistant ulnar nonunions: report of five preliminary cases, *Arch. Orthop. Trauma Surg.*, 2004, 124:26-30;
121. Kuznetsov S.A. et al.: Circulating Skeletal Stem Cells, *J. Bone Miner Res.*, 1997, 12, 1335;
122. Lee Y.M., Park Y.J., Lee S.J. et al.: The bone regenerative effect of platelet-derived growth factor-BB delivered with a chitosan/tricalcium phosphate sponge carrier. *J. Periodontol.* 2000, 71(3). 418-424;
123. Lee J.Y., Nam S.H. et al.: Enhanced bone formation by controlled growth factor delivery from chitosan-based biomaterials. *J ControlsRelease.* 2002 78(1-3): 187-197;
124. Lieberman J.R., Daluiski A., Einhorn T.A.: The Role of Growth Factors in the Repair of Bone, *J.B.J.S. Am.*, 2002, 1032-1044;
125. Lin X, Liang M, Feng XH. Smurf2 is a ubiquitin E3 ligase mediating proteasome-dependent degradation of Smad2 in transforming growth factor-beta signalling. *J Biol Chem.* 2000 275(47):36818-36822;

- 126.Lo C.H., Leung M., Baillieu C., Chong E.W., Cleland H.: Trauma center experience: flap reconstruction of traumatic lower limb injuries, *Zhongguo Xiu Fu Chongjian Wai Ke Za Zhi*. 2008 Aug., 22(8): 956-958;
- 127.Lucaciu D.: Update on the Drug Administration in the Treatment of Open Fractures, 2nd Balkan & 8th SOROT Congress of Orthopedics, Iași, România, 20-22 oct 1999;
- 128.Lucaciu O. D.: Grefa osoasă în chirurgia osteo-articulară, Ed. Napoca Star Cluj-Napoca, 1999;
- 129.Luo Z., Luo H., Jiang J., Song C., Gong M., Wang Y.: Pedicle flap transfer combined with external fixator to treat leg open fracture with soft tissue defect, *Foot Ankle Clin*. 2008 Mar., 13(1):145-156;
- 130.Lupescu V.: Traumatologie – Luxațiile și traumatismele membrelor, Vol.I, Fac. Medicină Constanța, 1998, 3-20, 61-72, 283-295;
- 131.Lupescu V.: Traumatologie și Ortopedie – curs pentru studenți, Ed. Muntenia&Leda, Constanța, 2001;
- 132.Lynch S.E., Williams R.C., Polson A.M. et al.: A combination of platelet derived and insulin-like growth factors enhances periodontal regeneration. *J. Clin. Periodontol.*, 1989, 16(8): 545-548;
- 133.Madsen JE, Hukkanen M, Aune AK, Basran I, Moller JF, Polak JF, Nordsletten L.: Fracture Healing and Callus Innervation after Peripheral Nerve Resection in Rats, *Clin. Orthop.*, June 1998, (351): 230-240;
- 134.Maier M., Schmitz C., Reffler H.J.: Extracorporeal Shock Wave Application in the Treatment of Pseudarthrosis, *European Journal of Trauma* 2003, no.5: 262-266;
- 135.Maintz G. Tierexperimentelle untersuchungen über die Wirkung der Ultraschallwellen auf die Knochenregeneration. *Strahlentherapie* 1950;82: 631-8;
- 136.Makino T., Hak D.J., Hazelwood S.J. et al.: Prevention of atrophic nonunion development by recombinant human bone morphogenetic protein-7; *J. Orthop. Res.*, 2005 23(3): 632-638;
- 137.Matiuță I., Mercea I., Andrași E., Horzan C., Diaconescu S.: Experiența noastră privind fractura deschisă de gambă, Conf Națională de Ortopedie și Traumatologie, Timișoara, 21-23 octombrie, 1998;
- 138.Mauney JR, Sjostrom S, Blumberg J, et al. Mechanical stimulation promotes osteogenic differentiation of human bone marrow stromal cells on 3-D partially demineralized bone scaffolds in vitro. *Calcif. Tissue Int.* 2004 74(5): 458-468
- 139.Maurer D.J., Merkow R.L., and Gustilo R.B.: Infection after intramedullary nailing of severe open tibial fractures initially treated with external fixation *J. Bone Joint Surg. Am.*, Jul 1989; 71: 835 – 838;
- 140.Mayer H., Scutt A.M., Ankenbauer T.: Subtle differences in the mitogenic effects of recombinant human bone morphogenetic proteins 2 to 7 on DNA synthesis on primary bone-forming cells and identification of BMP-2/4 receptor; *Calcif Tissue Int.*, 1996, 58(4):249-255;
- 141.Mayr E., Laule A., Suger G., Ruter A., Claes L.: Radiographic results os callus distraction aided by pulsed low-intensity ultrasound, *J. Orthop. Trauma*, Aug. 2001, 15(6): 407-416;
- 142.McGraw J.G., Edward V.A.: Treatment of open tibial shaft fractures, *A. JBJS* 1987, 69: 801-805;
- 143.McLeod K.J., Rubin C.T.: The effect of low-frequency electrical fields on osteogenesis, *J Bone and Joint Surg.*, July 1992, 74-A: 920-929;

144. Midy V., Plouet J.: Vasculotropin/vascular endothelial growth factor induces differentiation in cultured osteoblasts. *Biochem Biophys Res. Commun.*, 1994, 199(1): 380-386;
145. Miller N.C., Askew A.: Tibia Fractures. An Overview of evaluation and treatment, *J. Orthop. Trauma*, 2007 Aug, 21(7): S32-38;
146. Millward-Sadler SJ, Wright MO, Davies LW, et al. Mechanotransduction via integrins and interleukin-4 results in altered aggrecan and metalloproteinase 3 gene expression in normal, but not osteoarthritic, human articular chondrocytes. *Arthritis Rheum.* 2000 43(9):2091-2099;
147. Mittlemeier W., Braun C., Gradinger R.: Defect fractures of tibia-various forms of bone replacement, *Orthop. Rev.* 1987 Mar. 16(3): 154-164; Sartoris D.J., Kusnik C., Resnick D.: New concepts in bone grafting, *J. Bone Joint Surg. Br.* 2006 Oct., 88(10): 1351-1360;
148. Moed B.R., Wilson Carr S.E., Craig J.G., et al.: Calcium sulfate used as bone graft substitute in acetabular fracture fixation, *Clin. Orthop.*, 2003, 410:303-309;
149. Mollica Q., Gangitato R., Russo T.C., Longo G.: La quantificazione della deformazione relativa interfragmentaria nella fratture diafisarie dell'arto inferiore stabilizzate con chiodi endomidollari non rigidi: analisi della immagini radiografiche, *Giornale Italiano di Ortopedia e Traumatologia*, Settembre 1987, Voi. XIII, Fascicolo 3: 365-376;
150. Mundy GR. Regulation of bone formation by bone morphogenetic proteins signalling by Smurf 1 and inhibitory Smads. *Mol Biol Cell.* 2003 14(7):2809-2817;
151. Murolo C, Claudio F. Influenza degli ultrasuoni nei processi riparativi delle fratture. *G Ital Chir* 1952;8:897-903;
152. Muschler G., Nakamoto C Griffith Linda: Engeneering Principles of Clinical Cell-Based Tissue Engineering, *J.B.J.S*, 86-A:7, July 2004, 1541-1558;
153. Naique S.B., Pearse M., Nanchahal J.: Management of Sever Open Tibial Fractures: the Need for combined orthopedic and plastic surgical treatment in specialist centres, *Acta Orthop. Belg.* 1995, 61 Suppl. 1:212-215;
154. Nakase T., Nakahara T., Iwasaki M. Et al.: Clonal analysis of developmental potential of chick periosteum-derived cells: agar cel culture system, *Biochem. Biophys. Res Comm.* 1993, 195:1422-1428;
155. Nash T.J., Howlett C.R., Martin C. et al: Effect of platelet-derived growth factor on tibial osteotomies in rabbits. *Bone*, 1994 15(2): 203-208;
156. Neidlinger-Wilke C, Grood ES, Wang JHC, et al. Cell alignment is induced by cyclic changes in cell length: studies of cells grown in cyclicaly stretched substrates. *J Orthop Res.* 2001 19(2):286-293;
157. Nevins M., Giannobile W.V., McGuire M.K. et al.: Platelet-derived growth factor stimulates bone fill and rate of attachment level gain: results of a large multicenter randomized controlled trial. *J. periodontol.*, 2005, 76(12): 2205-2215;
158. Nolan P.C., Nicholas R.M., Mulholland B.J., Mollan R.A.B., Willson D.J.: Culture of human osteoblasts on demineralised human bone – possible means of graft enhancement, *J.B.J.S. Br.*, 1992, 74-B: 284-286;
159. Obadă B.: Contribuție la studiul consolidării fracturilor diafizare deschise de tibie- teză de doctorat, 2009;
160. Olson S.A.: Open Fractures of the Tibial Shaft, *JBJS*, Sep. 2006, 78-A(9), 1428-1437;

- 161.Orbeanu V.: Utilizarea grefei osoase vascularizate în ortopedie și traumatologie, Teză de doctorat, UMF „Carol Davila” București 2000;
- 162.Ostermann P.A. Seligson D., Henry S.L.: Local Antibiotic Therapy for Severe Open Fractures. A Review of 1085 consecutive cases, J.B.J.S. Br., 1995, 77-B(1):93-97;
- 163.Ostermann P.A., Henry S.L., Seligson D.: The Role of Local Antibiotic Therapy in the Management of Compound Fractures, Clin. Orthop. Relat. Res., Oct. 1993, (295): 102-111;
- 164.Panait Gh., Stoica C., Panait A., Lepadat C.: Mineralizarea biologică a osului, Ed. Tehnică, București, 1997, 10-177;
- 165.Paradis GR, Kelly PJ,: Blood flow and Mineral Deposition in Canine Tibial Fracture, J Bone Joint Surg. 57A: 220-226, 1975;
- 166.Park J., Gelse K., Franck S.et al.:Transegene-activated mesenchymal cells for cartilage repair: a comparison of primary bone marrow-, perichondrum/periosteum-, and fat-derived cells, J Gen Med. 2006 8:112-125;
- 167.Partio E.K., Tuompo P., Hirvensalo E., et al.: Totally absorbable fixation in the treatment of fractures of the distal femoral epiphyses. A prospective clinical study; Arch Orthop Trauma Surg., 1997, 116:213-216;
- 168.Peltier L.F., Speer D.: calcium Sulfate In: Habal MBReilly M.J. (eds). Bone Graft and Bone Graft Substitutes. Philadelphia: W.B. Saunders, 1992, 243-246
- 169.Peltier L.F.:The use of Plaster of Paris to Fill Defects in Bone, Clin Orthop., 1961, 21:1-31;
- 170.Perren SM (1991) Basic Aspects.In: Müller ME, Allgöwer M, Schneider R, et al., editors. *Manual of Internal Fixation*. 3rd ed. Berlin Heidelberg New York:Springer-Verlag. Șamotă I. Fixarea endomedulară elastică în fractura deschisă de gambă, Ed. C2 Design, Brașov 1999;
- 171.Pihlajamaki H., Kinnunen J., Bostman O., et al.: In vivo monitoring of the degradation process of bioresorbable polymeric implants using magnetic resonance imaging. Biomaterials, 1997, 18:1311-1315;
- 172.Pittenger M.F., Mackay A.M., Beck S.C. et al: Multilineage of potential of human mesenchyma stem cells, Science, 1999, 284:143-147;
- 173.Pollack N.A.: Timing of Debridement of Open fractures , J. Am. Acad. Orthop. Surg., 2006 Sept, 14(10): S48-S51;
- 174.Pop Al. :Fractura deschisă de tibie, University Press „Vasile Goldiș” Arad 1999;
- 175.Popescu M, Stabilizarea focarului în fractura deschisă de tibie, Ed. Sofitech SRL, București, 1997;
- 176.Prisell PT, Edwall D, Lindblad JB, et al. Expression of insulin-like growth factors during bone induction in rat. Calcif Tissue Int. 1993 53:201-205; Rockwood CA Jr, Green DP, Bucholz RW, et al Fractures in Adults. 4th ed Philadelphia: Lippincott.1996;
- 177.Rădulescu Al.,Iazikov DK, , Voinea A,: Pseudartrozele, Ed. Academiei RPR, București, 1962, 23-29, 39-42;
- 178.Rand JA, An KN, Chao EYS, Kelly PJ,: A Comparison of the Effects of Open Intramedullary Nailing and Compression Plate Fixation on Fracture Site Blood Flow and Fracture Union, J Bone Joint Surg. 63A: 427-442, 1981;
- 179.Raschke M., Rasmussen M.H., Govender S., Segal D., Suntum M., Christianssen J.S.: Effects of growth hormone in patients with tibial fracture: a randomized, double-blind, placebo- controlled clinical trial, European Journal of Endocrinology, 156(3):341-351;

- 180.Reddy V., Stevenson T.R.: MOC-PS(SM), CME article: Lower extremity reconstruction, *Chirurg.* 1996 Nov., 67(11): 1087-1092;
- 181.Rubin C., Bolander M., Ryaby J.B., Hadjiargyrou M.: The use of low intensity ultrasound to accelerate the healing of fractures, *J.B.J.S.* 2001, 83-A(2): 259-270;
- 182.Rubin C., Gross T., Qin Yi-Xiang, Fritton S., Guilak F., McLeod K.: Differentiation of the Bone Tissue Remodeling Response to Axial and Torsional Loading in the Turkey Ulna., *J. Bone and Joint Surg.*, Oct. 1996, 78-A: 1523-1533;
- 183.Ruedi T.P., Murphy W.M.: *Ao Principles of Fracture Management*, Davos, AO Publishing Stuttgart-New York, Georg Thieme Verlag, 2000, 45-53;
- 184.Russel G.V., King C., May Carmen, Pearsall A. W.: One Daily High Dose Gentamicin to prevent Infection in Open Fractures of the Tibial Shaft: A Preliminary Investigation, *South Med. J.*, 2001, 94(12):1185-1191;
- 185.Russel T.A.:*General Principles of Fracture Treatment*, Campbell Eighth edition: 725-785, Mosby Year Book, 1992;
- 186.Ryaby JT: Clinical effects of electromagnetic and electric fields on fracture healing, *Clin Orthop* 355(suppl):205, 1998;
- 187.Sakou T. Bone morphogenetic proteins: from basic studies to critical approaches. *Bone.* 1998 22:591-603;
- 188.Şamotă I. Fixarea centromedulară elastică în fractura deschisă de gambă, Ed. C2 Design, Braşov 1999;
- 189.Şamotă I.: Complex surgical team for limbs salvage in severe open fractures. The relation between anatomical reconstruction and final result., *Rev. Ortop.(SOROT)*, 1999, 9(1), 53-58;
- 190.Şamotă I.: Principii generale de tratament în fractura deschisă de tibie., *Rev. Ortop. Traum. (SOROT)*, 1999, 9(2), 69-80;
- 191.Sandberg MM, Hannu TA, Vuorio EI. Gene Expression During Bone repair. *Clin Orthop.*1993 289:292-312;
- 192.Sang-Hyun Park, Kim M. O'Connor, Harry McKellop: Interaction between Active Motion and Exogenous Transforming Growth Factor Beta during Tibial Fracture Repair, *J. Orthopedic Trauma*, 2003, 17(1): 2-10;
- 193.[Schemitsch EH](#), [Kowalski MJ](#), [Swiontkowski MF](#), [Harrington RM](#): Comparison of the effect of reamed and unreamed locked intramedullary nailing on blood flow in the callus and strength of union following fracture of the sheep tibia, [J Orthop Res.](#) 1995 May;13(3):382-9;
- 194.[Schemitsch EH](#), [Kowalski MJ](#), [Swiontkowski MF](#), [Senft D](#). Cortical bone blood flow in reamed and unreamed locked intramedullary nailing: a fractured tibia model in sheep, [J Orthop Trauma.](#) 1994 Oct;8(5):373-382;
- 195.Schmidmaier G., Wildemann B, Gabelein T. et al: Synergistic effect of IGF-1 and TGF-beta1 on fracture healing in rats: single versus combined application of IGF-1 and TGF-beta 1. *Acta Orthop Scand.* 2003 74(5): 604-610;
- 196.Schmidmaier G., Wildemann B., ostapowicz D. et al.: Long-term effects of local growth factor (IGF-1 and TGF-beta1) treatment on fracture healing. A safety study for using growth factors. *J Orthop Res.* 2004 22(3): 514-519;
- 197.Sen M.K., Miclau T.:Autologous iliac crest bone graft: should it still be the gold standard for treating nonunions?, *Injury.* 2007 Sep., 38(4): S7-12;
- 198.Sharrad W.J.W., Sutcliffe M.L., Robson M.J., Maceachern A.G.: The treatment of fibrous nonunion of fractures by pulsating electromagnetic stimulation, *J. Bone and Joint Surg. (Br)*, 1982, 84B: 189-193;

199. Shiamasaki S, Ling N, Identification and molecular characterization of insuline-like growth factor binding proteins (IGFBP-1,-2,-3,-4,-5 and -6). *Prog growth Fcator Res.* 1991 3:243-266;
200. Stevenson L., Li X.Q., Davy D.T., Klein L., Goldberg V.M.: Critical Biological Determinants of Incorporation of Non-Vascularized Cortical Bone Grafts, *J. Bone and Joint Surg.*, Jan. 1997, 79-A, 1-16;
201. Street J., Bao M., deGuzman L. et al.: Vascular endothelial growth factor stimulates bone repair by promoting angiogenesis and bone turnover. *Proc Natl. Acad. Sci. USA*, 2002 99(15): 9656-9661;
202. Südkamp N, Haas NP, Flory PJ, et al. (1989) [Criteria for amputation, reconstruction and replantation of extremities in multiple trauma patients]. *Chirurg*; 60 (11):774–781;
203. Sungaran J., Harris I., Mourad M.: The Effect of Time to Theatre on Infection Rate for Open Tibia Fractures, *Journal of Surgery*, 2007 October, 77(10): 886-888;
204. Tardif G, Hum D, Pelletier JP, et al. Differential gene expression and regulation of the bone morphogenetic protein antagonists follistatin and gremlin in normal and osteoarthritic human condrocytes and synovial fibroblasts. *Arthritis Rheum.* 2004 50(8):2521-2530;
205. Tarkka T., Sipola A., Jamsa T. et al.: Adenoviral VEGF-A gene transfer induces angiogenesis and promotes bone formation in healing osseous tissues. *J. Gene Med.*, 2003, 5(7): 560-566;
206. Termaat M.F., Den Boer F.C., Bakker F.C. et al: Bone morphogenetic proteins. Development and clinical efficacy in the treatment of fractures and bone defects; *J.B.J.S Am.*, 2005, 87(6):1367-1378;
207. Tomoaia Ghe.: *Curs de traumatologie osteo-articulară*, Editura medical universitară „Iuliu Hațieganu” Cluj-Napoca, 1999;
208. Trenholm A., Landry S McLaughlin K. Et al: Comparative fixation of tibial plateau fractures using BSM, a calcium phosphate cement, versus cancellous bone graft, *J Orthop. Trauma*, 2005, 19(10): 698-702;
209. Trippel S.B., Contts R.D., Einhorn T.A., Mundy G.R., Rosenfeld R.G.: Growth Factors as Therapeutic Agents, *J. Bone and Joint Surg.*, Aug. 1996, 78-A: 1272-1286;
210. Tscherne H, Gotzen L: *Fractures with soft tissue injuries*, Berlin, 1984, Springer-Verlag;
211. Tu Y.K., Yen C.Y., Ma C.H., Yu S.W., Chou Y.C., Lee M.S., Ueng S.W.: Soft-tissue injury management and flap reconstruction for mangled lower extremities, *ANZ J Surg.* 2007 Aug. 77(8): 690-694;
212. Vats A., Trolley S.N., Buttery D.K., Pollak M.: The Stem Cell in Orthopaedic Surgery, *J.B.J.S.*, Vol. 86-B, No. 2, March 2004, 159-164;
213. Vladimarsdottir G, Goumans MJ, Rosendahl A, et al. Stimulation of Id1 Expression by Bone Morphogenetic Protein Is Sufficient and Necessary for Bone Morphogenetic Protein Induced Activation of Endothelial Cells. *Circulation.* 2002 06:2263-2270;
214. Weitz-Marshall A.D., Bosse M.J.: Timing of closure of open fractures, *JBJS* 1990 Jan. 72(1):125-128; Russell G.G. Henderson R., Arnet G.: Primary or delayed closure for open tibial fractures, *Injury* 2007 Aug. 38(8): 879-889;
215. Welch R.D., Zhang H., Bronson D.G.: Experimental tibial plateau fractures augmented with calcium phosphate cement or autologous bone graft, *J Bone Joint Surg Am.*, 2003 85:222-231;

216. Werner C.M.L., Pierponte Yvone, Pollack N.A.: the Urgency of Surgical Debridement in the Management of Open Fractures, *J. Am. Acad. Orthop. Surg.*, 2008, July, 16(7): 369-375;
217. Wickham M.Q., Erickson G.R., Gimble J.M. et al.: Multipotent stromal cells derived from the infrapatellar fat pad of the knee, *Clin Orthop Relat res.*, 2003, 412:196-212;
218. [Wing-Hoi Cheung](#), [Simon Kwoon-ho Chow](#), [Ming-Hui Sun](#), [Ling Qin](#), [Kwok-Sui Leung](#): Low-Intensity Pulsed Ultrasound Accelerated Callus Formation, Angiogenesis and Callus Remodeling in Osteoporotic Fracture Healing, *Ultrasound in Medicine and Biology*, [Volume 37, Issue 2](#) , Pages 231-238, February 2011;
219. Wirsching R.P., Eich W., Misselbeck E.: Langzeitergebnisse nach extracorporaler Stosswellentherapie bei pseudarthrosen, *Stosswelle*, 1998, 1:22-26;
220. Yamamuro T. Bone Bonding Behavior and Clinical Use of A-W Glass-Ceramic. In: Urist M.R., O'Connor B.T., Burwell R.G.: *Bone Grafts, Derivates and Substitutes*. Oxford: Butter-worth-Heinemann Ltd., 1994:245-259;
221. Yamanji T., Ando K., Nakamura T., Washimi O., Terada N., Yamada H.: Femoral shaft fracture callus formation after intramedullary nailing: a comparrison of interlocking and Ender nailing, *J. Orthop. Sci.*, June 2002, 7(4): 472-476;
222. Yamanji T., Ando K., Wolf S., Augat P., Claes L.: The effect of micromovement on callus formation, *J. Orthop. Sci.*, 2001, 6(6):571-575;
223. Yan M., Dang G.T.: The preliminary result of osteoid callus allograft for bone healing, *Zhongguo Xiu Fu Chong, Jian Wai Ke Za Zhi*, Jan. 2001, 15(1): 57-59;
224. Yazar S., Lin C.H., Wei F.C.: One-stage reconstruction of composite bone and soft-tissue defects in traumatic lower extremities, *Plast. Reconstr. Surg.* 2006 Jun., 117(7): 2468-2475;
225. Yeh C., Unda R., Lee J.C.: Osteogenic protein-1 differentially regulates the mRNA expression of bone morphogenetic proteins and their receptors in primary cultures of osteoblasts; *J. Cell Physiol.*, 2000, 185(1):87-97;
226. Yeh L.C., Tsai A.D., Lee J.C.: Osteogenic protein-1 (OP-1, BMP-7) induces osteoblastic cell diferentiation of the pluripotent mesenchymal cell line C2C12; *J. Cell Biochem.*, 2002, 87(3):292-304;
227. Youn I., Suh J.K., Nauman E.A. et al.: Differential phenotypic characteristics of heterogenous cell population in the rabbit periosteum, *Acta Orthop.* 2005, 76:442-450;
228. Yu X., Hsieh S.C., Bao W. Et al.: Temporal expression of PDGF receptors and PDGF regulatory effects on osteoblastic cells in mineralizing cultures, *Am J Physiol.* 1997 272 (5 pt 1): C1709-C1716
229. Yusuf S, Collins R, Peto R. Why do we need large, simple randomised trials? *Stat Med* 1984;3:409-22;
230. Zalavras C.G., Marcu R.E., Levin L.S., Patzakis M.J.: Management of Open Fractures and subsequent Complications, *Infect Dis Clin North Am.* 2005 Dec., 19(4): 915-929;
231. Zalavras C.G., Patzakis M.J.: Open Fractures: Evaluation and Management, *J. Am. Acad. Orthop. Surg.*, 2003 May/June, 11(3): 212-219;

232. Zeichen J., van Griensven M., Bosch U., the proliferative response of isolated human tendon fibroblasts to cyclic biaxial mechanical strain. *Am J Sport Med.* 2000 28(6):888-892;