

**UNIVERSITY "LUCIAN BLAGA" - SIBIU**

**FACULTY OF MEDICINE "VICTOR PAPILIAN" - SIBIU**

**"PHLEBOGRAPHY IN EVALUATION OF CHRONIC  
VENOUS INSUFFICIENCY "**

**SUPERVISOR:**

**PROF. DR. DAN SABĂU**

**PROF. DR. ROMEO ELEFTERESCU**

**STUDENT:**

**DR. CIPRIAN RADU ȘOFARIU**

**MOTTO:**

**„ TRUE SCIENTIST KNOWS HOW TO FIND IN HIS  
EXPERIMENTS ANSWER TO WHAT HE SEARCH, BUT TO  
SEEK A RESPONSE FOR WHAT HE DIDN'T ASKED”**

**CLAUDE BERNARD**

*Definition:*

Chronic venous insufficiency (van der Molen) is a clinical syndrome with different etiopathogeny, prognosis and therapeutic that is subsequent to chronic disturbances of venous circulation, especially in the lower limbs, resulting in significant changes of interstitial space, lymphatics and skin.

Chronic venous insufficiency includes two subdivisions clinically very similar, but different in terms of etiopathogenesis, therapeutics and prognosis:

1. Superficially chronic venous insufficiency, representing the late stage of superficially veins insufficiency and varicose disease, sometimes surnamed as "varicose symptomatic complex" the inadequacies of junctions of the large veins, internal and external saphenous, and / or perforating vein insufficiency.

All of these conditions can be treated successfully, so that failure superficially chronic venous has a good prognosis. Varicose veins are not the actual cause of failure superficially chronic venous insufficiency (L. Gherasim), but the more likely to have a common cause with them.

2. Chronic deep venous insufficiency is the postphlebotic syndrome, the consequence of occlusions and deep vein functional disorders.

The causes of these disorders can be suppressed in exceptional cases, so that chronic deep venous insufficiency postphlebotic syndrome not can be cured and requires long term treatment. It often puts problems for both: patient and doctor.

# Ultrasound and Phlebographical Diagnosis of Peripheral Chronic Venous Insufficiency

## 1. PURPOSE

Determination of radio-imaging characteristic aspects of peripheral chronic venous insufficiency under and over fascial and assess the role of ultrasound and phlebography in its diagnosis.

## 2. OBJECTIVES

Analysis of relevant epidemiological factors in causing varicose veins and deep vein thrombosis (endogenous: anthropological, anatomical and physiological, genetically, constitutional, sex, age, endocrine, pregnancy, obesity, health status and exogenous: physical and social).

Morphological analysis of static and dynamic aspects of ultrasound, color Doppler and spectral in varicose disease, DVT and post thrombotic syndrome, compared with phlebography.

Establish the role of the radio-imaging methods in the diagnosis of Chronic Venous Insufficiency - CVI.

## 3. MATERIALS AND METHODS

Patient selection:

People who presented for ultrasound and phlebography investigation in the Laboratory of Radiology and Medical Imaging from Pediatric Hospital of Sibiu, Radiology and Medical Imaging Laboratory of Sibiu's County Emergency Hospital, Clinic "Body and soul-Prof. Dr. Ilie Craciun " Clinic "Medica Nursing Plus" with clinical diagnosis of varicose veins, deep vein thrombosis and post thrombotic syndrome.

Diagnostic methods used:

For analysis were used groups of patients (432 patients only with ultrasound, 54 patients only with phlebography examination, and 87 patients with ultrasound followed by phlebography, 10 controls for ultrasound examinations, and 3 for the phlebography).

Ultrasound examinations were performed using several types of ultrasound (mostly listed first):

- Siemens Acuson X500,
- Siemens Acuson X300,
- Hi Vision Hitachi EUB 5500 (Hitachi Medical Corporation, Kashiwa, Japan).

Phlebography examinations were conducted with two types of devices: Philips Telediagnost (Philips Eindhoven, Netherlands, 2000), digital fluoroscopy with Easy Vision imaging station type and Swissray ddr Multi-System (Hochdorf, Switzerland, 2000 ) rontgen complete digital machine.

Were examined patients with clinical diagnosis of

- acute and chronic venous thrombosis
- varicose disease
- venous valvular insufficiency
- vein stenosis
- pseudo aneurysms of veins
- at the request of patients with subjective complaints of venous disease

Method and data collection period: longitudinal prospective study: January 2004-October 2011.

Standard ultrasound examination consisted of:

- Write of patient personal data on:
  - age,
  - sex,
  - area of origin,
  - profession,
  - personal history of veins pathology
  - family history of veins pathology
  - clinical signs
- The clinical examination performed by the radiologist
- Systematic ultrasound exploration of the veins of the lower limb examined simultaneously with the contra lateral limb veins with parameters and images recording
- Analysis and outcome of the result
  - Transducers were used with the wide dynamic range of:
    - 5-10 MHz for Siemens ultrasound machines
    - 6.5-13 MHz for Hitachi ultrasound machine.

Examination technique was adapted according to the explored segment, age, and muscle mass and subcutaneous tissue thickness.

For evaluation of upper limb veins were used frequencies between 5 and 10 MHz. Examinations began with axial sections thus identifying the simultaneous venous and arterial structures and allow the pressure and compressibility testing, followed by longitudinal sections needed to study blood flow characteristics and searching obstruction. Upper limb position varied from anatomical position for forearm and 2/3 distal of the arm, the examination in abduction of 1/3 proximal of the and underarm and back into anatomical position with the head rotating to the opposite subclavian vein for subclavian vein exploration.

Protocol to investigate upper limb veins (38), modified as sense of examination:

Hand veins:

- a. forearm veins to identify the origins of cephalic vein and basilic vein, median vein trajectory
- b. Envelope elbow: median basilic vein and median cephalic vein, cephalic vein, basilic vein and brachial veins
- c. cephalic vein in the arm and pectoral groove and confluence to subclavian v.
- d. basilic vein in the arm and confluence to axillary v.
- e. subclavian vein (morphology, dynamic data)

Examination of leg veins has been made with two types of transducers:

- Low frequency convex 3.5-5MHz for IVC (Inferior Vena Cava) and vessels located in the pelvis

Common iliac veins and internal and external iliac veins and

- Linear transducers with frequencies between 5 and 10 MHz for the rest of the veins

Leg.

This was a close examination of contiguous up to the knee, after which followed some reference levels (38):

- a. common iliac veins
- b. external iliac veins
- c. common femoral vein
- d. sapheno-femoral junction and greater saphenous vein's trajectory, tributaries, communicating veins
- e. superficial femoral vein (in upper third, medium and lower third of Hunter channel)

f. popliteal vein

g. sapheno-popliteal junction and small saphenous vein's trajectory, tributaries, vv. communicating

h. posterior tibial veins

i. anterior tibial veins

Static examination was performed involving the venous system venous trunks able basal view to characterize them: lumen, wall, track, spontaneous flow and its parameters using Doppler techniques. Modulation-induced respiratory and adjacent arteries were also pursued in particular linked to the functioning valves.

Examination of dynamic morphological and functional behavior of veins intended to highlight the application of different diagnostic maneuvers for blood flow augmentation (muscle compression upstream of the explored site, passive or active rising of the member, foot finger movement) or to stop it (abdominal or muscle compression downstream of the explored site, the Valsalva maneuver, cough, tourniquet application). Muller maneuver was mainly used for valvular reflux view.

Note that all ultrasound examinations were performed by one physician reviewer, radiologist, in the person of the author of this thesis.

Standard phlebography examination consisted of:

Write of patient personal data similar to that of ultrasound.

Prior preparation of patients consisted of:

- Assessment of serum creatinine,
- Informing them of the procedure,
- Administration of antihistaminic medication (antiH1) the day and morning prior examination and
- Injection IV a dose of hydrocortisone succinat sodic 1-2mg/Kg 5-10 minutes prior to administration of contrast.

Performing venous puncture raised frequently problems, marked edema, poor state of superficial venous bed, resulting sometimes delaying of the investigation.

Patient and medical staff will be protecting from radiation with aprons, small aprons and cervical collars. Patients positioning of examined member in anatomical position. The examination tables allow quick mobilization regions of interest manually. Tourniquet application and injection of contrast substance will be followed by acquisition of serial radiographs, or movie.

For evaluation of lower limb venous system were applied technique of anterograde combined and complete phlebography (Cid Dos Santos) and variants with changes mainly in the amount of contrast injected and no use anticoagulant especially in pediatric patients.

Sometimes we practiced 30° tilt table examination of the Philips Telediagnost to generate a dilation of leg veins and get a slight delay in transit of the contrast.

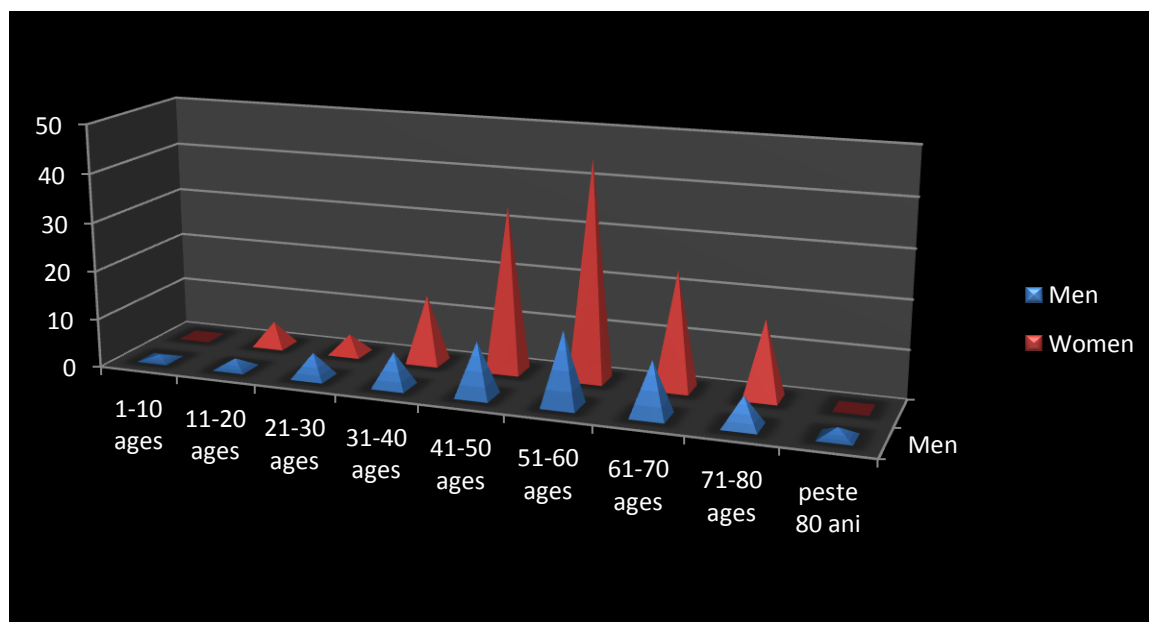
In some cases underwent reinjection of a new dose of approximately 30 ml contrast for a better assessment of valvular system in conditions of stasis, expiration and increased intra-abdominal pressure.

Consideration of the existence of relevant epidemiological factors in causing varicose veins and deep vein thrombosis (endogenous: anthropological, anatomical and physiological, genetically, constitutional, sex, age, endocrine, pregnancy, obesity, health status and exogenous: physical and social).

Although the studies were performed on samples from patients relatively limited compared with prospective and retrospective analyzes involving thousands of subjects and investigated cases were selected by doctors, clenched for a few necessary considerations of epidemiology of the disease on the venous system.

Distribution of studied patients by age and sex:

It may be noted that most patients suffering with venous system diseases are grouped around five decades, six and seven of life with a peak between 51 and 60 ages.



Part of vein diseases are studied in medical pathology (cardiologists and internists): DVT and superficial thrombophlebitis, post thrombotic syndrome. Varicose disease, venous dysplasia, trauma and tumors as well as some of the complications of venous disease belong surgical pathology.

This large chapter of vein diseases requires a multidisciplinary approach. Radiologists, physicians specialized in functional explorations; laboratory doctors bring their important contribution to the diagnosis and treatment monitoring.

Opie (59) established an incidence of approximately 5.2% of chronic venous insufficiency on a group of 500 patients, taking into account only those subjects who backflow valve of the common femoral vein is associated with clinical symptoms, other patients with reflux following to be monitored.

Our study demonstrated the following:

The incidence of varicose veins (truncal varicose and spider) by Brand (81), Carpentier (82), Chiesa (83) and London (84) was approximately 17% for men and 31% in women.

The incidence of varicose veins in the studied groups was 71% of which 46% women and 25% male, with a ratio of about 2:1 in favor of females, similar to the Chiesa's multicenter study.

Patients belonging to urban or rural are difficult to determine because the address mentioned in identity card that assigns the label of rural area to approx. 23% of patients require some major adjustments.

Large-scale migration of population from villages to cities during communism and its depopulation after 1989 looking for a job outside the country, through bankruptcy mono industrial cities which captured rural labor (commuters) and practicing subsistence agriculture have left Romanian villages population aging and economic theft.

Low accessibility to the doctor in these localities, reduced importance of aesthetics in old age and hard physical work underlying predominantly urban distribution of patients investigated.

Superficially chronic venous insufficiency present in several clinical forms: edema, and other or purple dermatitis, stasis eczema, varicose dermal hypodermatitis, white Miliary atrophy, culminating with venous ulcers healed or active, appropriate CEAP clinical stages III-VI, is 26% of patients studied.

As the Pathogenesis of varicose veins, venous walls meiotonia (meiotonia: it. - reduced functional capacity and reactivity) has a proven genetic influence of the high percentage of patients with a family history of hydrostatic varicose veins among relatives of I degree.

Transmission appears to be polygenic predisposition and not limited to reduced synthesis of collagen and endo parietal hexosamine that increase distensibility (85).

FOXC2 gene mutation, 16q24 is found in common distensibility of varicose veins and lymphedema.

Among patients with a family history of varicose disease 37% of them said they inherited the disease from both parents.

Note that disease transmission to offspring has a high percentage in patients with varicose disease group, so 47% of them have children with clinical manifestations in various stages: from spider veins to varicose veins with edema and trophic changes.

Pregnancy plays an important role in varicose veins or in their emphasis on women susceptible, 54% of patients considering pregnancy as a trigger point. The higher incidence of varicose veins in multiparous women compared with nulliparous: ratio 3:1 and tend to balance the ratio men: women after menopause, indicates the involvement of female hormones in the genesis of varicose veins.

Parvu and Gherasim (2.3) consider that large amounts of estrogen secretion induce connective tissue laxity and increased venous walls distensibility.

Oral contraceptives cause endodermic varicose veins. Endocrine status during pregnancy may lead to opening of fistula arterial-venous fistula responsible for venous congestion.

Hypervolemia of pregnancy and impairing blood flow in leg veins due to large abdominal vein compression by gravid uterus and increased blood flow in ovarian veins are factors that cause lower limb venous distension.

The hypothesis of primary varicose veins of the legs genesis, through arterial venous shunts is based on the finding of increased oxygen saturation and a higher temperature in blood from varicose segments than in that of non varicose veins or in mixed venous blood.

Occupational factors play an important role in the genesis of varicose veins. The professional tier included in our study was a large: the profession involved prolonged standing: doctors (predominantly surgical specialties), priests, waiters, teachers, hairdressers, and workers in assembling lines, and those characterized by an excessive sedentary: cashier, clerk, and IT.

Profession remains the only adjuvant in the context of genetic predisposition existence. There are patients with varicose disease do not subscribe to the panoply prone professions.

However, even in the professions likely, most do not develop disease.

Professional predisposing factor is a necessary but not sufficient to trigger disease.

On the other hand short exercises during working hours that make the muscle pump function or venous channels that favor reduced risk of developing varicose veins even the professionals likely.

Inactivity and obesity are reflected in the development of varicose veins in people susceptible because any such heaviness mechanical blood flow in both veins and in the deep subcutaneous (ascites, pregnancy, abdominal tumors, various compression, thrombosis) lead to the production of varicose veins by increasing intra abdominal pressure.

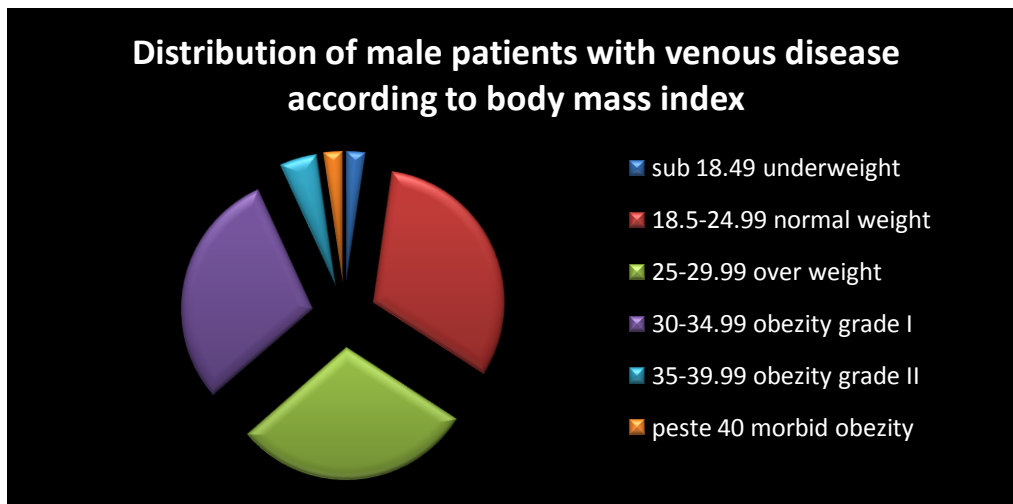


**Endogenous factors:**

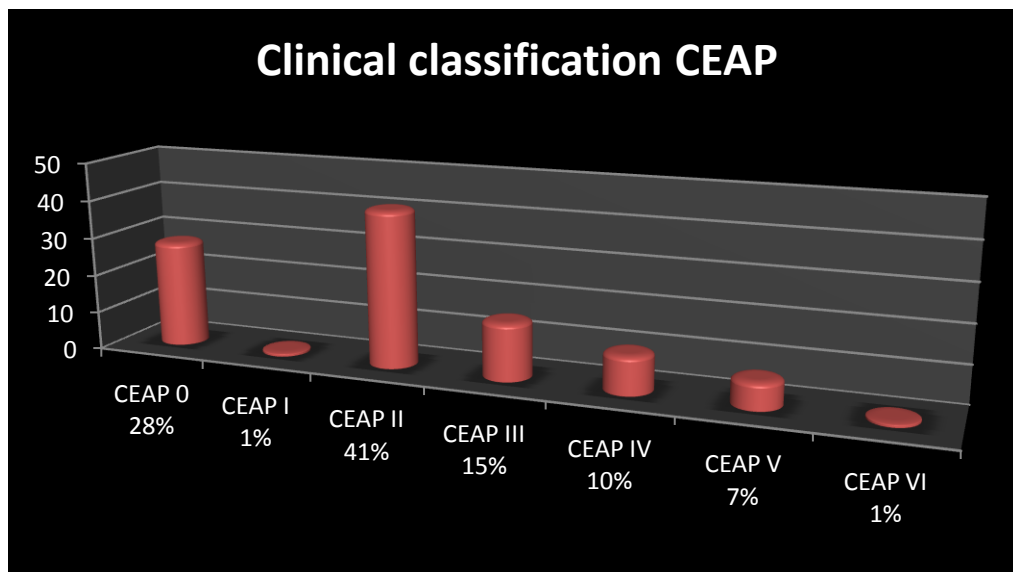
1. anthropological - biped resort
2. Anatomical and physiological
3. Genetically
4. Constitutional type
5. Sex
6. Age
7. Endocrine factors
8. Pregnancy
9. Obesity
10. Health

**Exogenous factors:**

1. Physical (geography, microclimate)
2. Labor.



**Clinical classification (CEAP) of patients with varicose disease:**



- Class 0 - no visible or palpable signs;
- Class 1 - spider or reticular veins;
- Class 2 - varicose veins;
- Class 3 - edema;
- Class 4 - skin changes due to venous disease (pigmentation, eczema, venous lipodermo)

sclerosis);

Class 5 - skin changes as defined above with healed ulceration;

Class 6 - skin changes as defined above with active ulceration.

Most patients in the study group were classified into class 2 (varicose veins). A significant percentage of patients were presented for evaluation of imaging techniques to conduct appropriate therapeutic approach.

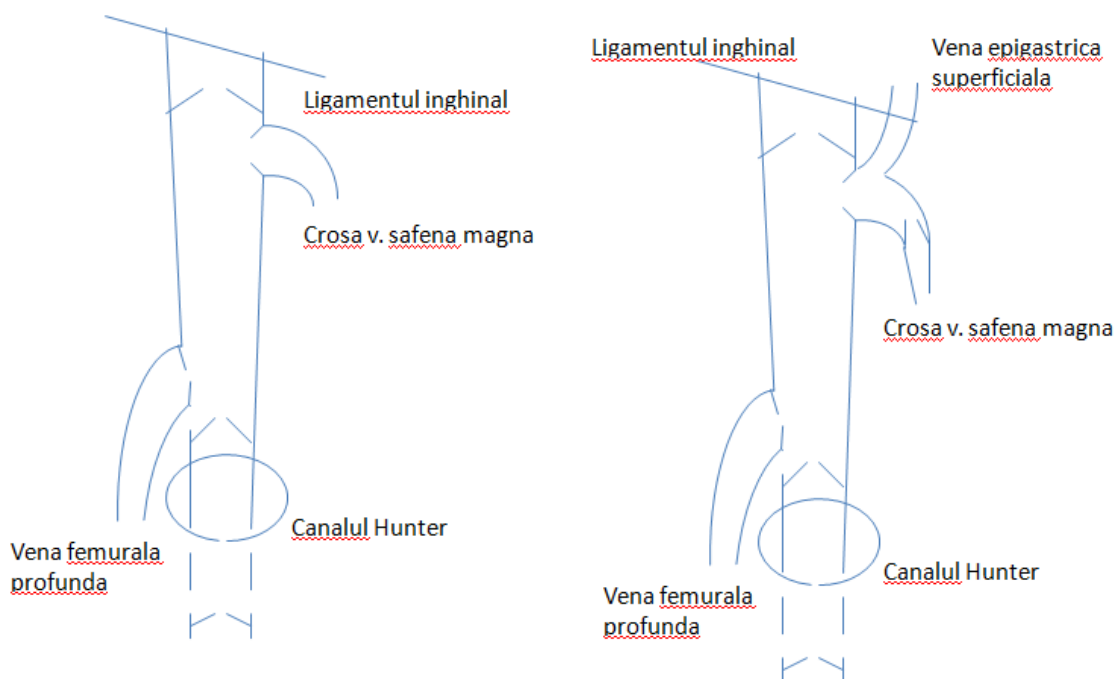
The presence of a high percentage of patients with trophic changes and varicose ulcer reveals some persistent gaps in the health education of patients, in their adherence to treatment, and in the absence of uniform, standardized, but also appropriate to each patient therapeutic strategies.

### *Backflow of valves*

Constantly have revealed sapheno femoral junction with ostium's valve.

In 14% of cases the same ostium of greater saphenous vein arch and superficial epigastric vein was noticed, in this situation common ostium and saphenous vein arch were provided with their own valves.

Valves were identified consistently present in the superficial femoral vein FV proximal end and femoral vein before penetration in the adductor's channel.

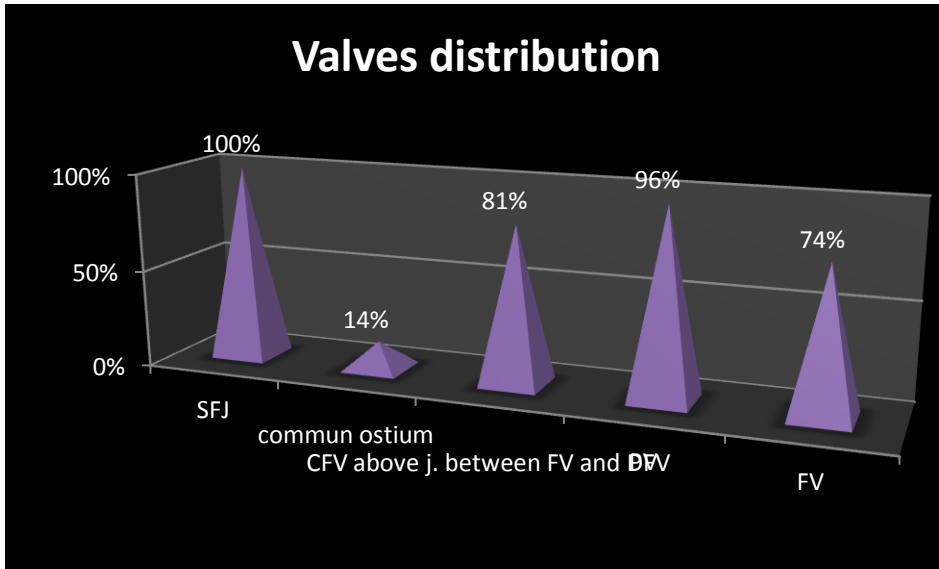


In 81% of cases was identified a valve above sapheno-femoral junction and one below the inguinal ligament.


A valve often identified (96% of cases) was located in the popliteal vein, without precise positioning.

Morphological ultrasound examination of the distal femoral vein in the groin is difficult for reasons of equipment, not very deep penetrating of linear transducers, decreases image sharpness especially in obese patients, and no possibility of total compression of the vein to subjects with well represented muscles.

Generally run out portion of adductors channel, near to the distal ring is relatively easy to exam, the vein is sometimes better viewed at this level than the artery.



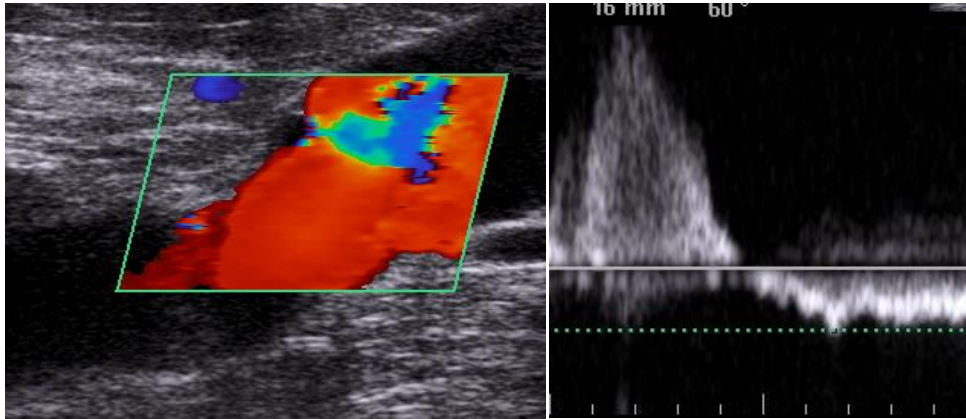
This backflow presence at SFJ valves in the long saphenous vein in patients with varicose disease:



Ostium's reflux can be caused by functional valves insufficiency in the context of increasing size of SFJ with incomplete closure of the valve (most cases) or congenital or acquired defects of valves cusps.

Reflux can be modulated respiratory and / or by arterial pulse.

Depending on the flow may be variable from fine reflux induced by the dynamic maneuvers to highlight reflux with a massive peak at maneuvers that induce intra abdominal increased pressure.

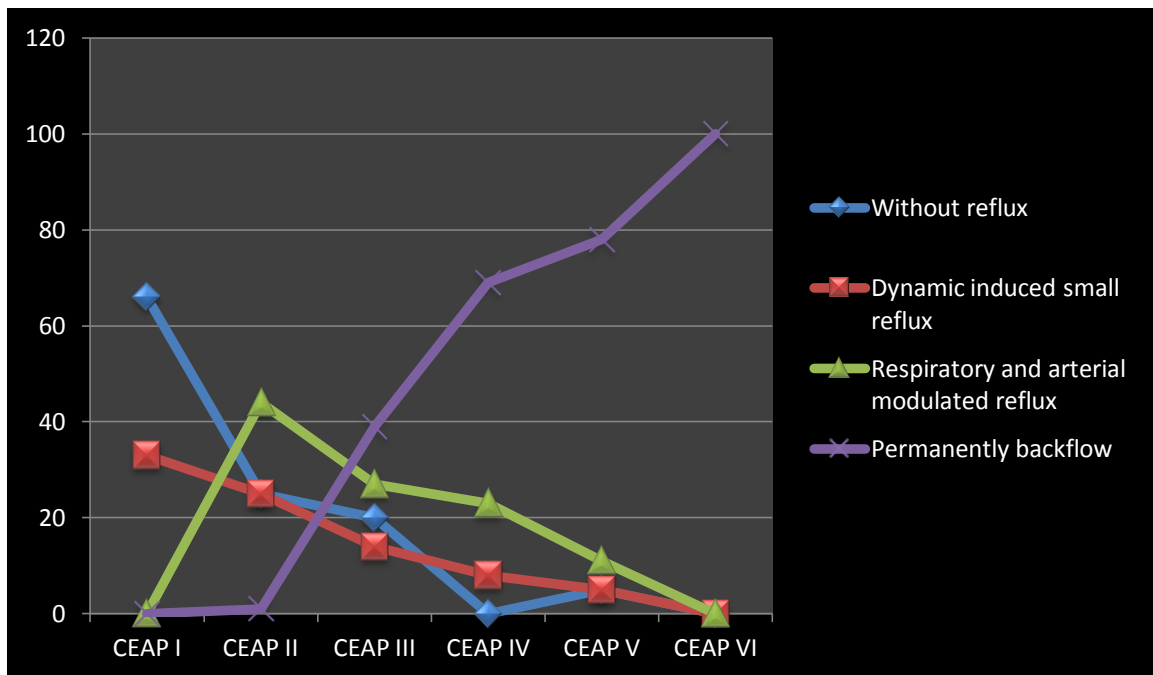


*Complete reversal of flow direction (massive reflux), respiratory modulated with a defect of the anterior cusps of the SFJ valve seen in color flow.*

Illustration of massive reflux in duplex Doppler: two-dimensional view reveals a slow flow with haematic macro aggregates, "smoke flow", which is reversed at some point become vortex. Spectral Doppler image illustrates high amplitude positive waves (flow speed of about 40 cm / sec, corresponding to respiratory modulation)

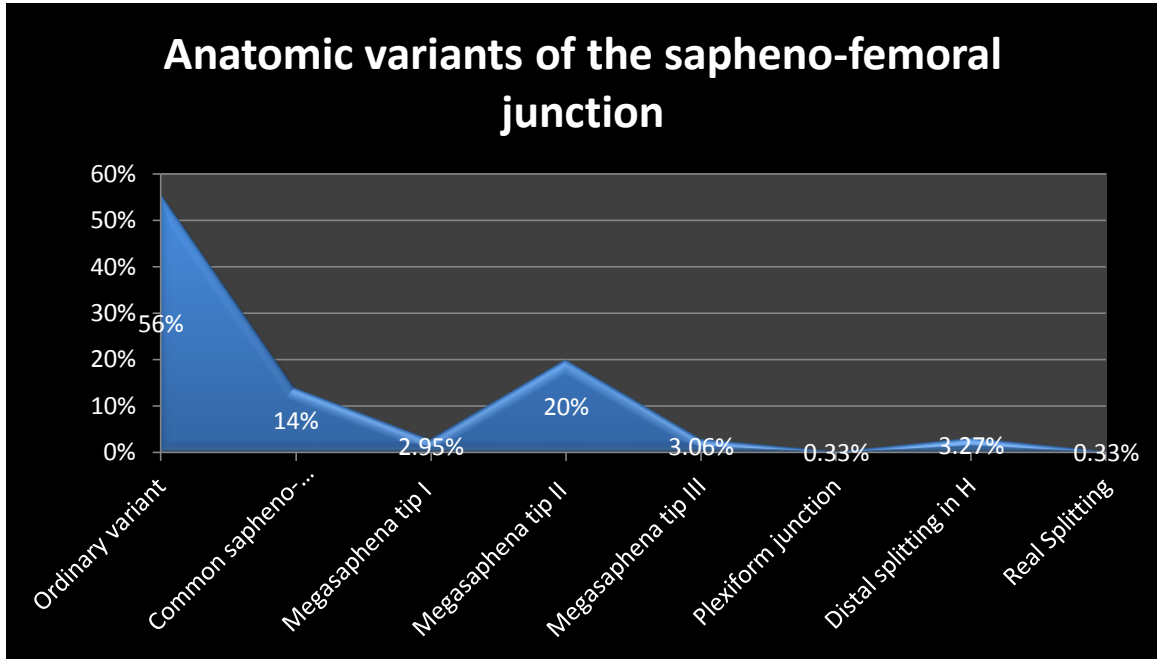
The incompetence of saphenous-femoral junction's valves is correlated with the clinical severity of varicose veins, CEAP advanced stages are associated with massive reflux which was missing in the early stages of disease.

*Correlation between level of ostial reflux and severity of varicose disease illustrated by CEAP classification:*

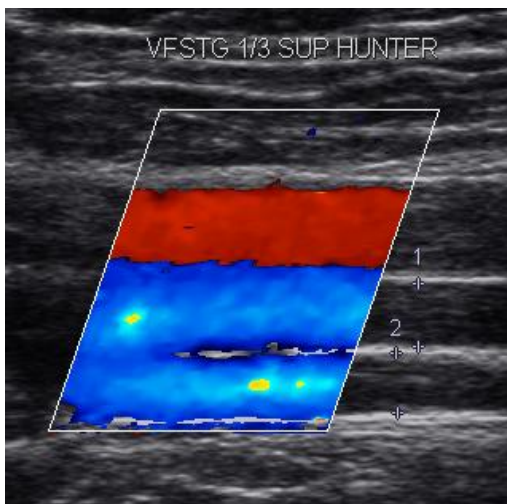


**Anatomic variants of the sapheno-femoral junction:**

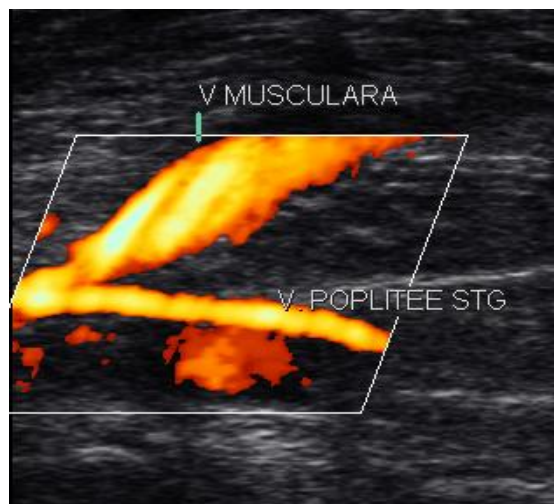
Sapheno-femoral junction may take different aspects: from the classic version of a solitary ostium of the long saphenous arch proposed by Blanchemaison (86) to the existence of a common sapheno-epigastric core (morpho-functional unit often highlight ultrasound).



In terms of sensitivity of ultrasound to detect variations caused by sapheno-femoral junction and its tributaries is difficult to make a real estimate because anatomical studies doesn't agree themselves there is very large differences between different authors. For example Prof. Jose Ciucci's (88) appearance on of the Medical University of Buenos Aires, in a study published in 2010 by a group of 100 subjects, at necropsy, only 9% said that they had the classic scheme of sapheno-femoral junction. On the other hand Professor Jesus Sanchez, Spain in 2001 published an intraoperatively study by a group of 136 patients: the classical scheme of sapheno-femoral junction is identified in 46% of subjects.



*FV duplication*

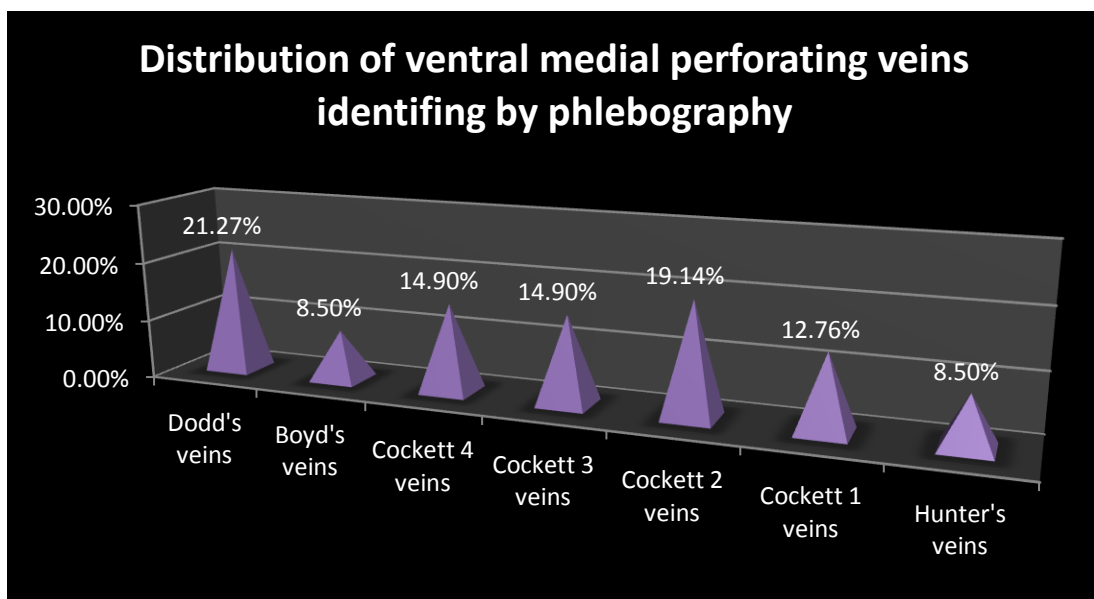
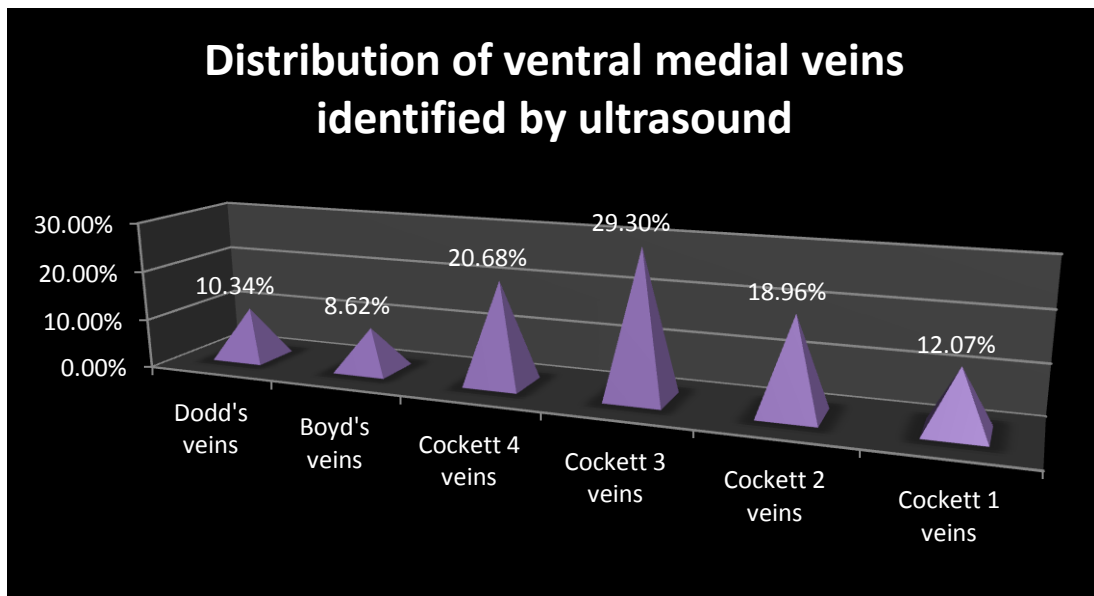


*Hypoplastic popliteal vein replaced by the muscle branches veins*

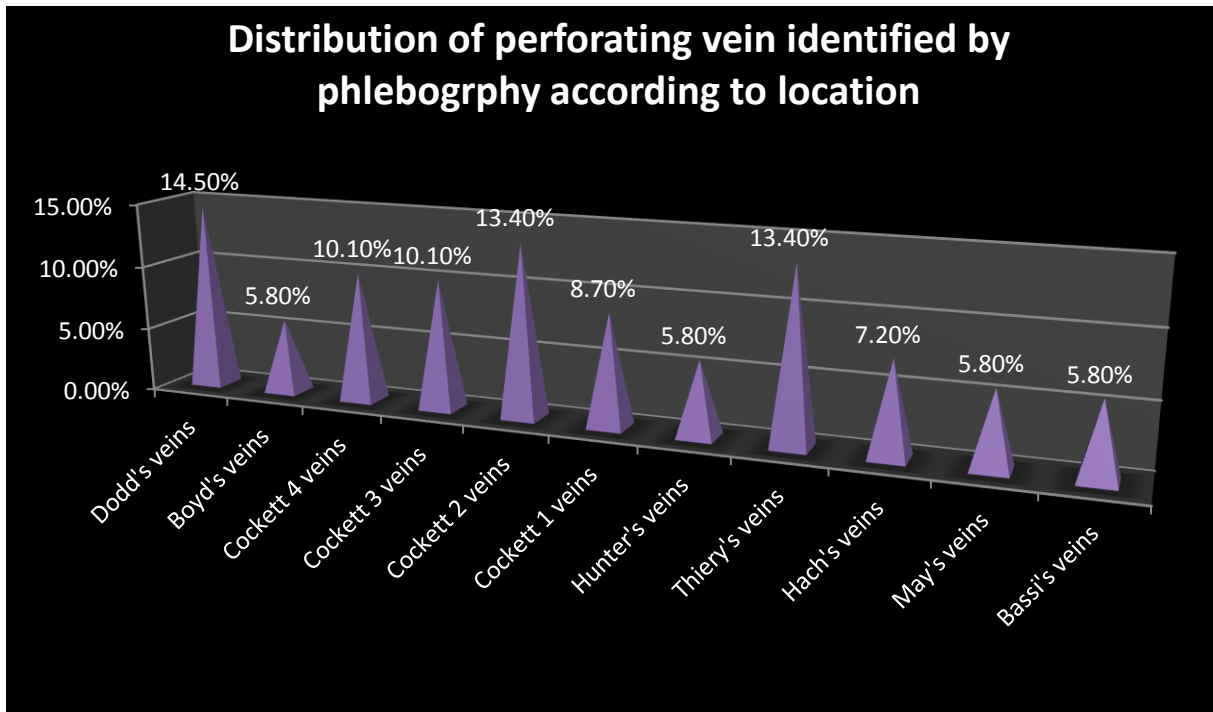
Perforating veins play an important role in hemodynamic status of the lower limbs, being a system of "locks" with two valve, ensuring a unidirectional flow, facilitated by muscle pump, from the surface low pressure system to the deep high pressure system.

Although the sensitivity of ultrasound in detecting perforating veins is lower than the phlebography, B-mode and duplex examination bring additional information about flow sense and flow speed.

In the study group were identified through ultrasound examinations pathologic perforating veins changes about for 37.4% of subjects with varicose disease and near for 47.2% of patients which had a history of superficial thrombophlebitis or deep vein thrombosis, with no significant difference between the sexes.



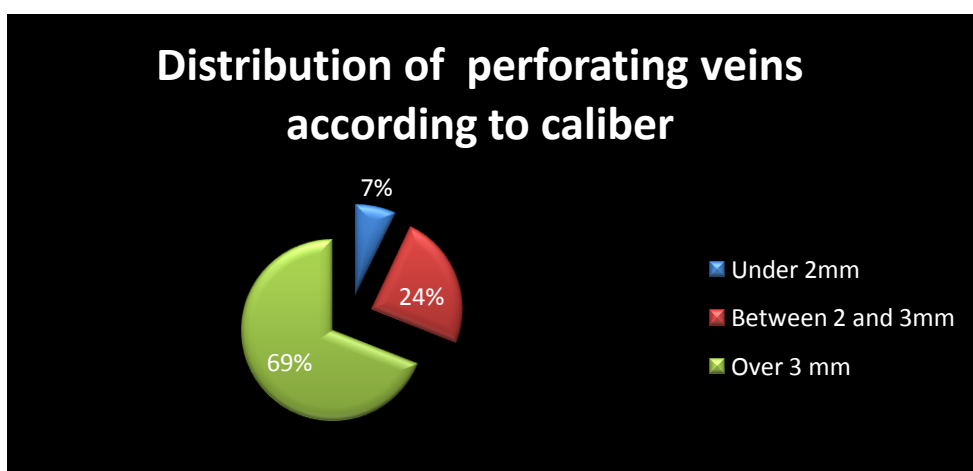
*Comparing the two methods of investigation ultrasound and phlebography can say that the identification of perforating veins from group of interest Cockett and Boyd was in similar percentages.*



Although performance of phlebography is superior to ultrasound in terms of discovery perforating veins according to location, slightly more difficult with ultrasound, It should be noted that not all perforating veins detected by phlebography are pathologically altered.

At a routine ultrasound perforating veins without pathological changes detection is difficult. We may conclude that the discovery of aperforating veins with ultrasound should raise a question to examiner.

Size variations must be correlated with other aspects: number, serpiginos or linear course, Baun configuration, flow direction: normally superficial to deep, flow sense changes as a result of dynamic maneuvers application, body mass index, presence of pathological changes in the superficial or deep venous system, existence of clinical signs attributable to peripheral venous system disease.

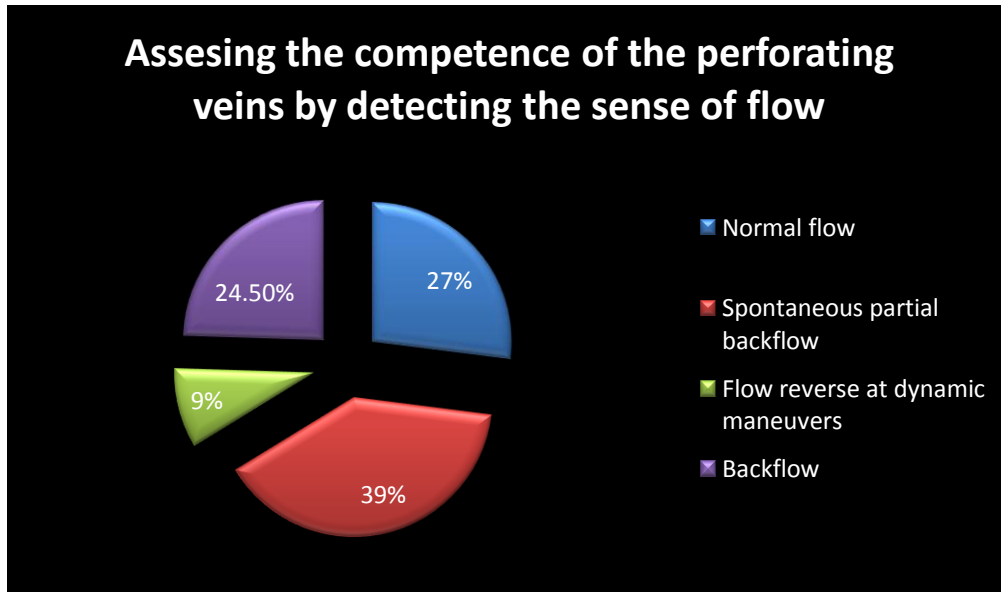


An important aspect in the perforating veins was to assess the competence of the valvular system indirectly by detecting the sense of flow using color Doppler examination.

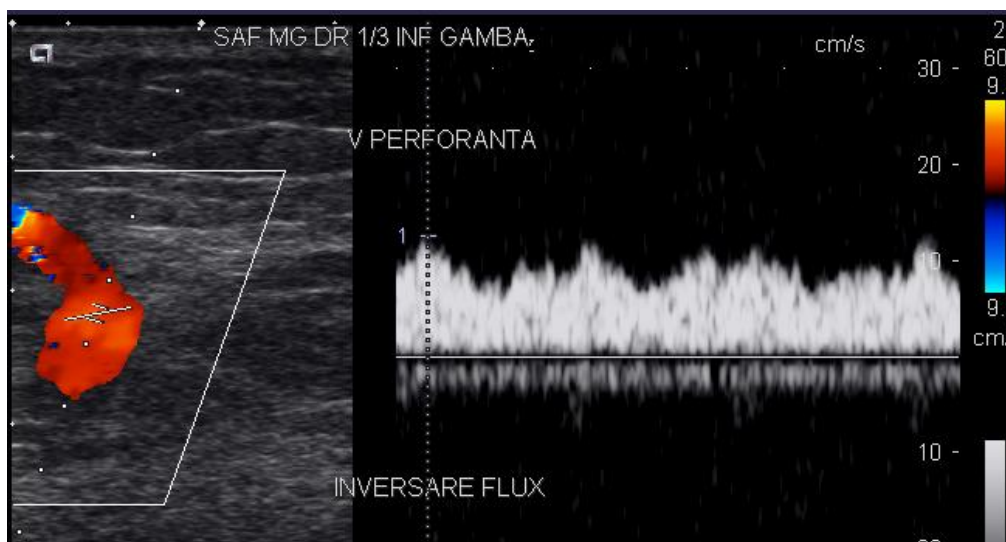


Doppler spectrum is less sensitive to establish flow sense due to the continuing need to adapt and rapidly changing Doppler angle, positivity or negativity of the waves at small changes in sense of perforating veins.

It's watched the flow sense both spontaneously and after application of dynamic maneuvers, careful to avoid false positive results generated by perforating veins serpiginos trajectory or inadequate adjustment of Doppler angle to vessel trajectory.



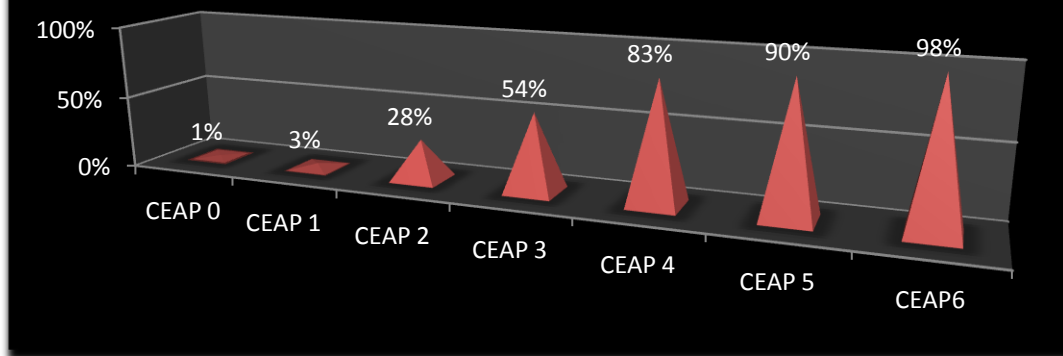
*Complete reversal of flow sense on color flow and spectral Doppler*



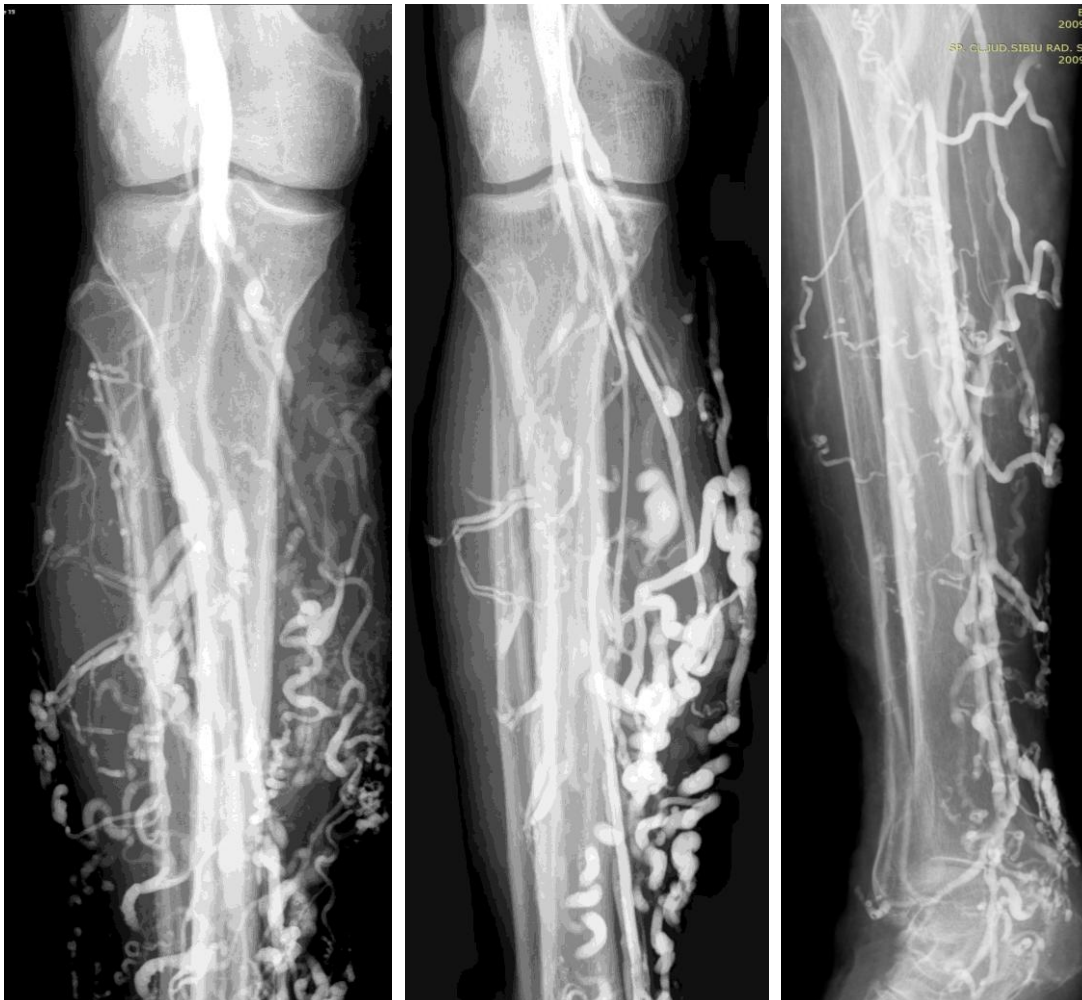In terms of establishing a correlation between the topography of perforating vein valves and their incompetence should be noted that most of them belong to Cockett 3, 2, 1 perforating veins located about 15-20cm over internal malleola 76% of cases. Lower percentages were recorded in the third upper leg 15% (Boyd and Cockett 4) and 9% in 1/2 lower thigh (Dodd and Hunter).



## Correlation between CEAP classification and Cockette 3,2,1 perforating veins with incompetent valves



As you can see the severity of varicose veins is closely related to impairment of perforating vein valves; number of subjects with incompetent perforating veins is greater in stages 4, 5 and 6 of the clinical classification.

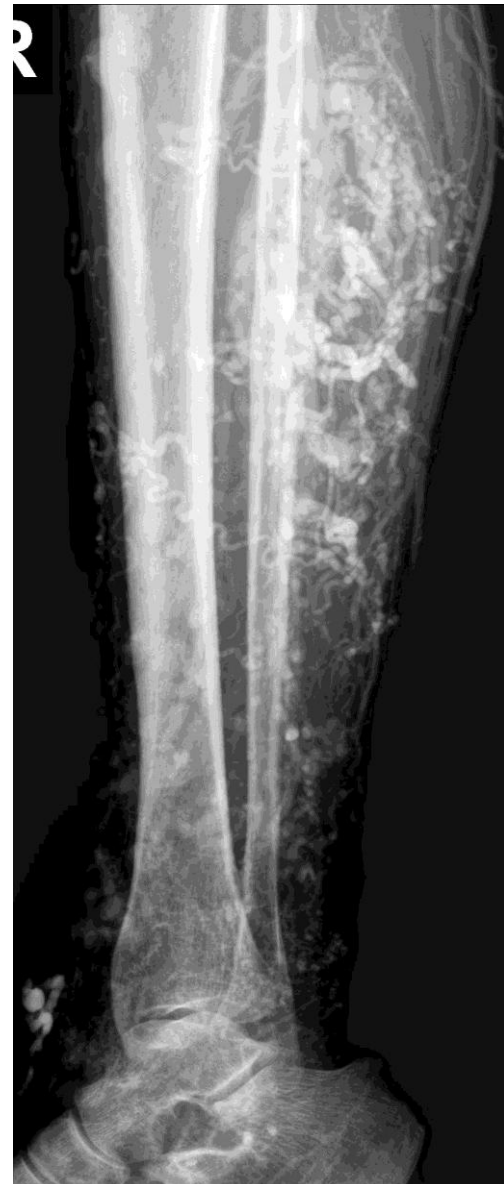
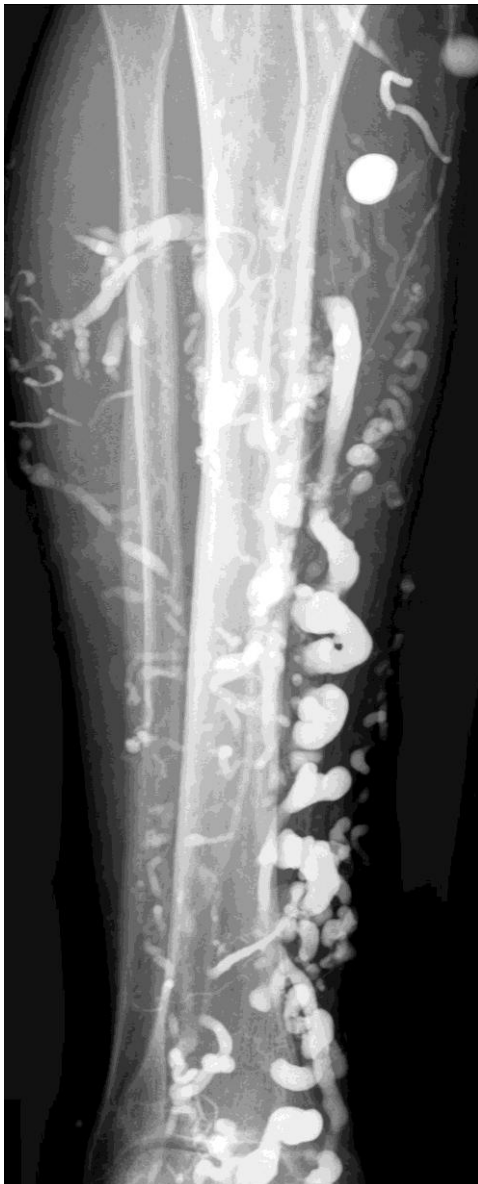
Perforating veins on phlebography stands out much easier than ultrasound, where the device performance, during which it may grant attention, ecographer's versatility can influence their detection.

Perforating veins are easier to quantify like morphology, number and classification Baun on phlebography, but the sense of flow, and their velocityies, insufficient valves are easy to quantify at ultrasound exam.

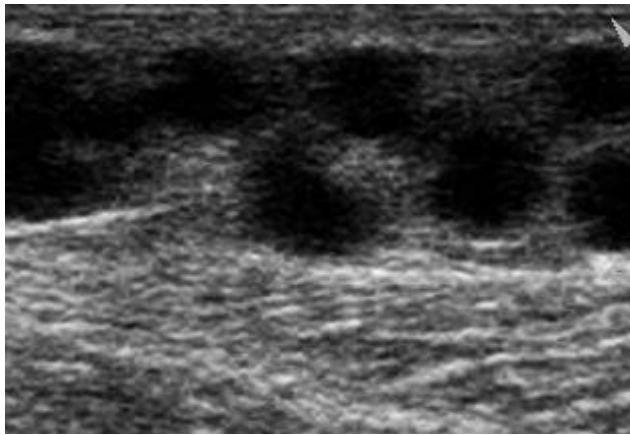
Like Boyd perforating veins connecting long saphenous vein tributaries in the region under internal condylar with popliteal vein, tibial and peroneal veins, there is a constant group of veins, most doubles (Baun type II and III) located postero-external linking vein tributaries to lesser saphenous vein or communicating between two saphenous and peroneal veins.

Like these three groups is similar others located at the junction of 1/3 top and 1/3 average 1/3 medium and the junction of the third medium and 1/3 lower, somewhat similar vein Cockett 4, 3 and 2, but located laterally. These perforating veins open in extreme situations: advanced varicose disease, DVT.

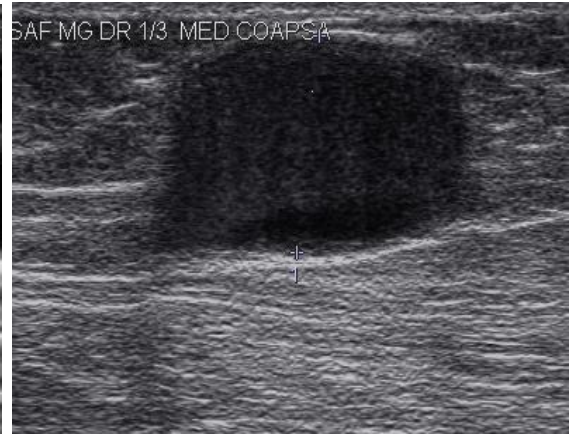


In terms of diagnosis phlebography and ultrasound can tell whether it is primitive varicose veins, secondary varicose veins or symptomatic for a deep venous malformation.

In varicose veins with abnormal location on external front or back of thigh, phlebography reveals communicating vein place which maintains backflow and require to be interrupted.



*Varicose on greater saphenous*

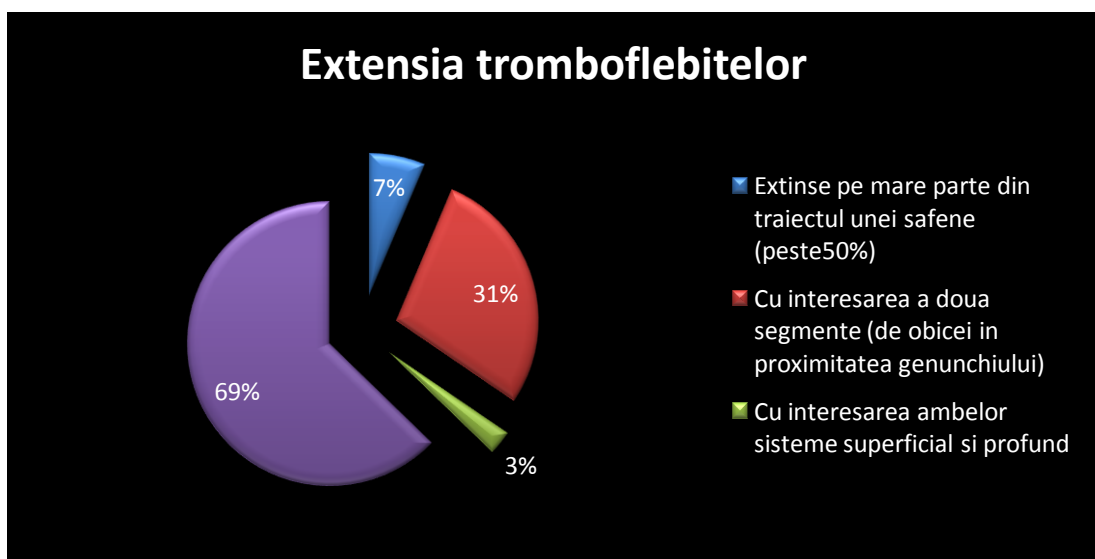


*„Smoke flow” in swelling of the sinus*

### Trombophlebitis

In group of patients with varicose disease examined, 10.47% of them had changes of acute thrombophlebitis (variable echogenic image into vessels associated with Celsius described clinic signs), while only 7% had variable echogenic images without acute inflammatory phenomena-old thrombophlebitis.

Patients with recurrent thrombophlebitis associated with varicose veins, thrombophlebitis here excluding recurrent tumor, or those associated to Burger disease, 4 cases were relatively few 0.92%; recurrence of disease due to the late presentation at physician and long evolution thanks to lack adherence at drug therapy or surgical treatment refusal.



In DVT ultrasound B-mode discover next changes:

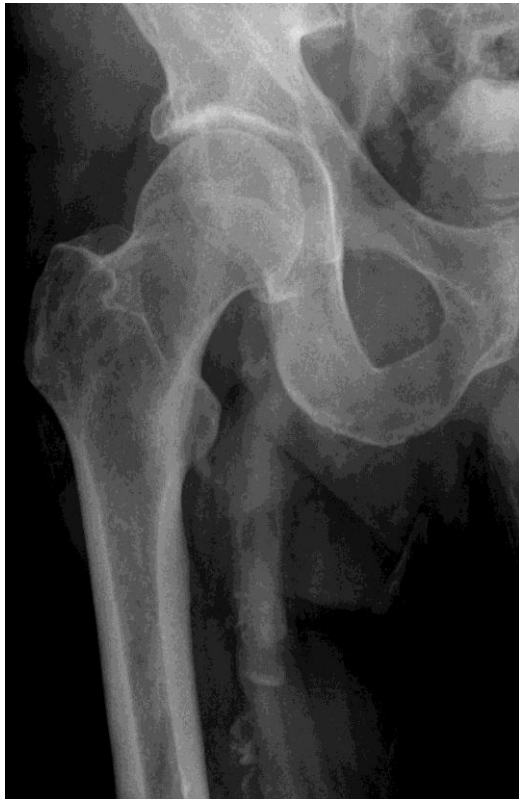- Thrombus presence into vessels as a hypoechoic – or anechoic image with thin echogenic rim
- Vessel compression test positive
- An important sign is the significant increase in caliber of thrombosed vessel toward the contralateral vein,
- Immobility of venous valves in an intermediate position
- Lack of venous dilatation at dynamic maneuvers (compression downstream, increasing venous pressure)
- Slow flow with emphasizing spontaneous the flow echogenicity "smoke flow"
- Changes in the soft tissues: edema (from slight increasing of hypoderm echogenicity to the presence of fluid bays more visible near fascia), cellulitis, hematoma (hypo-echogenic recently, hyper echogenic-old)

Spectral Duplex exam reveals in DVT:

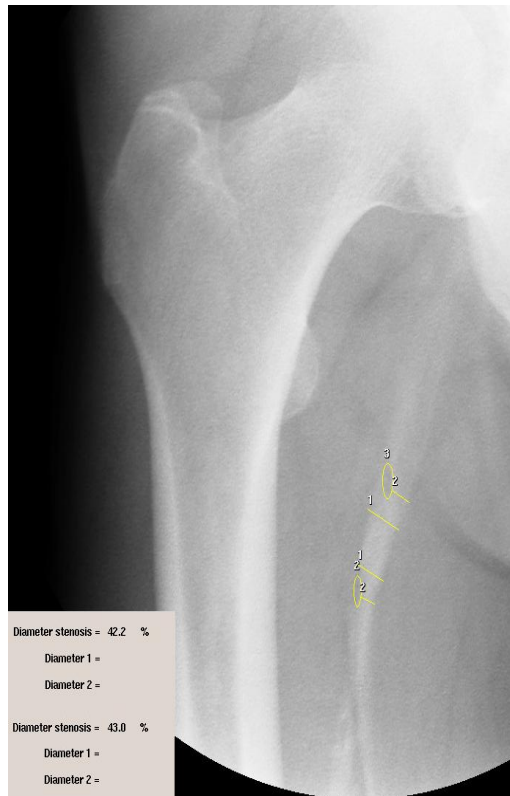
- Spontaneous or induced absence of Doppler waves in thrombosed vessel.
- If is a partially obstructive thrombus, or a partially permeable channel It can be detect an changed Doppler signal than contralateral vein (reduced amplitude waves, the absence of their respiratory and / or heart modulation) (Keogan) (115). There is no flow changes at dynamic maneuvers (compression or leg raising does not increase flow upstream). These changes occur gradually depending on the degree of obstruction or on the caliber of free channels.

Color flow Doppler findings in DVT:

- Full or partially absence ("color gap") of the lumen filled with color, viewed on perpendicular sections spontaneously and after dynamic maneuvers. (Prandoni) (106)
- Assess the degree of obstruction on axial sections
- Assessment of cranial limit of thrombus on longitudinal sections
- Measuring the working lumen illustrating the slow flow by Power / Angio Doppler and the fastest by Color Flow
- Power Doppler examination is a slight tendency to overestimate the size of the patent channel.

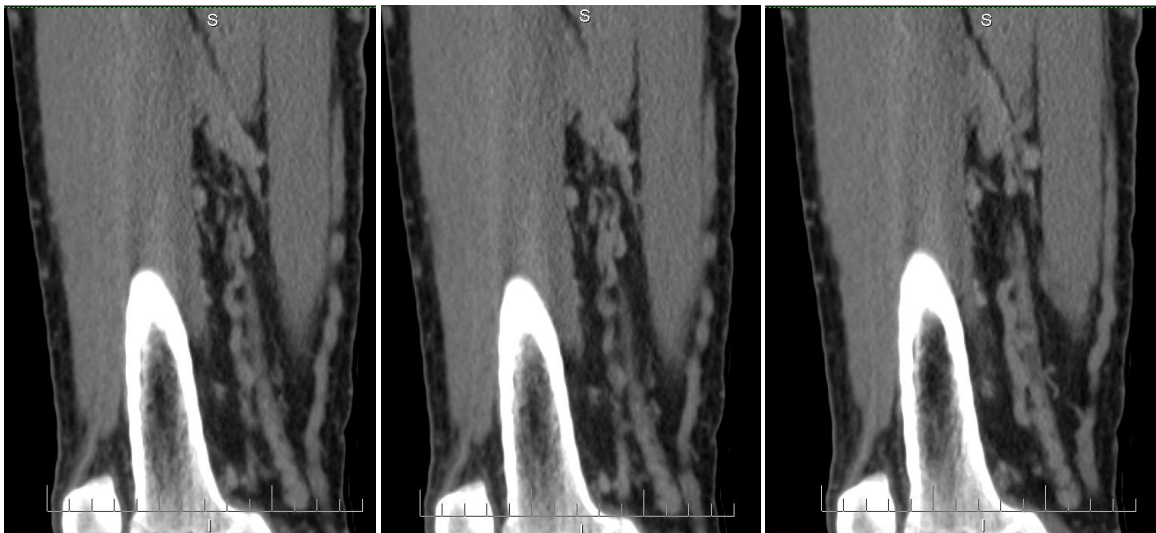


*DVT highly incomplete sinus opacification*



*Sinus thrombus*

Phlebography findings: absence or partial opacification of vascular lumens / removed, irregular wall contour, hemodynamic response of the superficial system, enlargement of perforating veins.

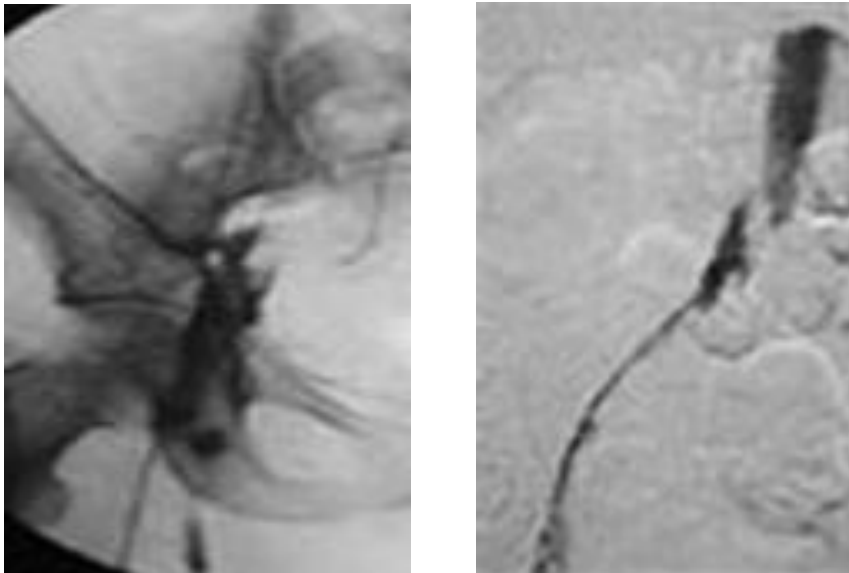


*CT appearance of sinuous channel of repermeabilisation of right femoral vein in Hunter channel, sinuous veins accompanying small arms. Magna saphenous varicose vein with*

## POSTTHROMBOTYC SYNDROME

According to Douz, quoted by Dudea and collaborators, ultrasound posttrombotic syndrome aims to highlight four vascular syndromes confounding in varying degrees:

- venous obstruction syndrome (thrombus, absence of flow)
- restrictive syndrome (diameter reduction and vein plasticity by fibrosis)
- repermeabilization syndrome (spontaneous and prolonged venous reflux due to destruction of venous valves)
- alternate syndrome, hemodynamic and morphological changes of the superficial venous system (high flow velocities, flow, non modulated).



*View iliac axis. Postthrombotic syndrome iliac shaft with fine repermeabilization channel comparative aspect between phlebography with classic image (right) and phlebography with digital subtraction image(left).*

On chronic dialysis patients, contrast venography has played an important role in terms of evaluating the venous system before performing the arteriovenous fistula, maturation and its functionality and last but not least, complications occurred: thrombosis, pulmonary embolism secondary to thrombosis, aneurysm, theft syndrome (development of collateral flow) with the affected limb ischemia, bacterial infection (from local inflammatory signs to endocarditis).

Lately, with the ultrasound machine evolution, phlebography was placed in obscurity, with only limited guidance in assessing clenched for a few arteriovenous fistulas.

## EVALUATION OF ARTERIOVENOUS FISTULA

Ultrasound provides to surgeon sufficient informations to achieve a successful intervention, the morphology of vessels concerned: trajectory (location, depth) caliber, arterial wall (atheromatosis presence at chronic dialysed patients, heavy smokers, dyslipidemia - all of them make difficult surgical procedure) and venous, and especially data on blood hemodynamics (speed, sense of flow).

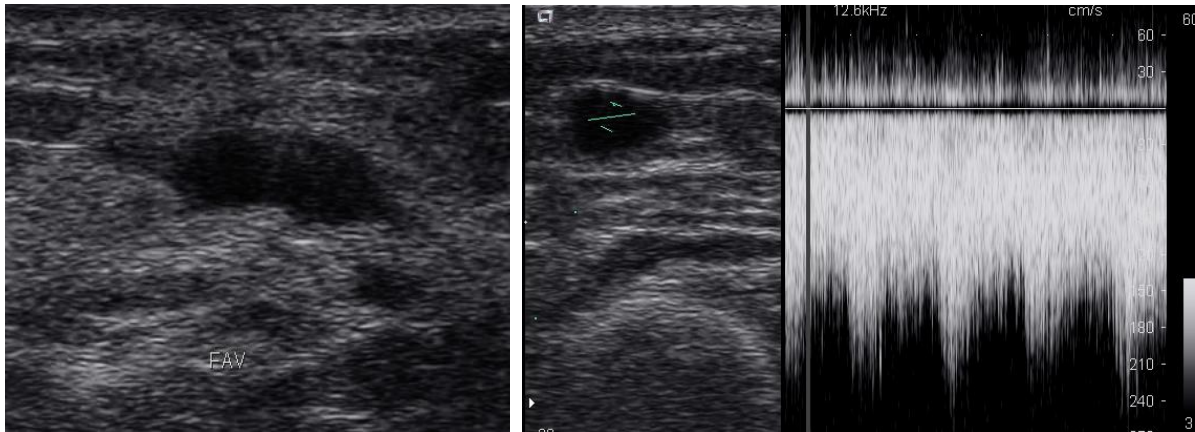
In addition to superior *dynamic* data than phlebography, ultrasound has clenched for a few undeniable advantages: examination of both system of vessels: the vein and the artery, absence of irradiation - repeatability for monitoring the evolution, absence of contrast



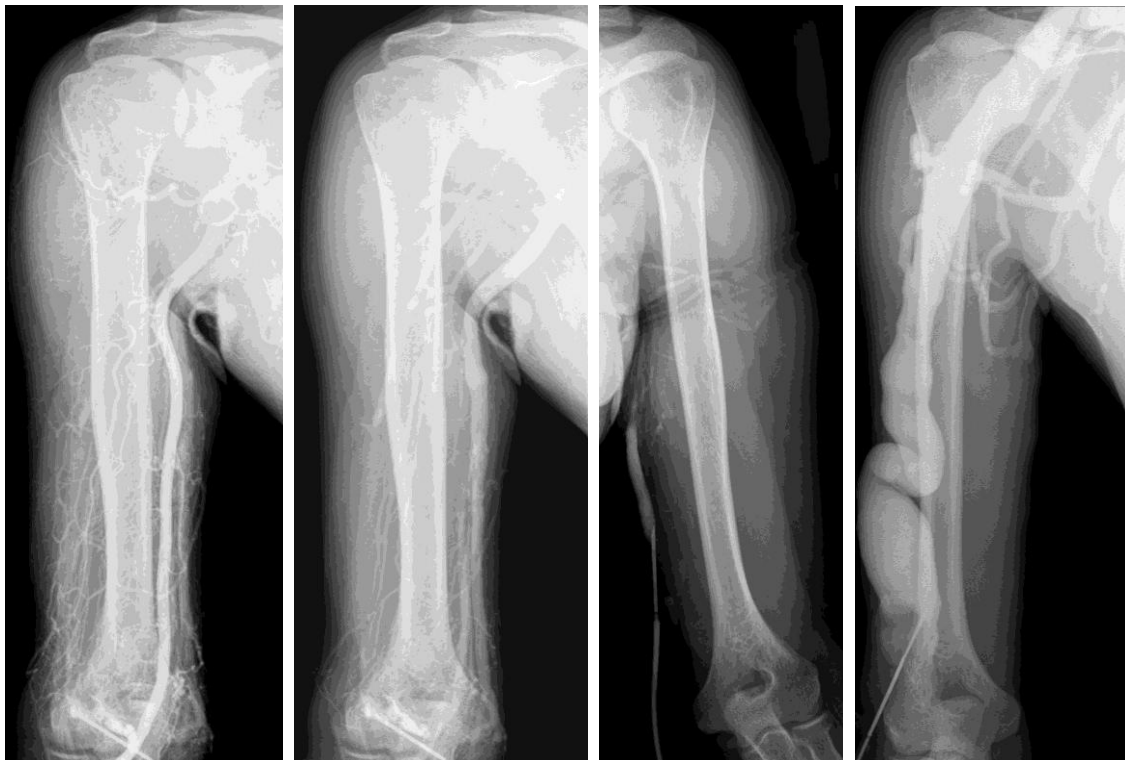administration (contrast = side effects and may induce chronic renal failure), relatively easy accessibility.

An artery with 3mm minimum size and minimum systolic speed 40-50cm/sec, and a vein caliber minimum 3-3.5mm, with a good heart are prerequisites to achieve a mature functional arteriovenous fistula.

Phlebography's advantages consists in detection of all small tributaries of the vein anastomosed which can lead to the syndrome of theft and to highlight cranial portions of the cephalic and subclavian veins less accessible to ultrasound examination in obese or well represented muscle mass patients, and all venous tributaries of the armpit.



*Arteriovenous radial-cephalic mature fistula (B-mode and spectral Doppler appearance)*



*Normal and pathological appearance of arteriovenous fistula*

## CONCLUSIONS

Ultrasound is the imaging method of first choice in exploring the peripheral venous system due to accessibility, repeatability, noninvasive nature, lack of contraindications and side effects.

Ultrasound imaging provides semiological informations necessary and sufficient to carry out differential and positive diagnosis of venous disease, allowing assessment of their progress with or without treatment.

Ultrasound is a method available for screening and diagnosis of suffering venous leg giving relevant information about both hemodynamic (speed, sense of flow, functioning valves, perforating veins) and the morphological appearance.

Exploring limits of ultrasound we could mention the fact that ultrasound is laborious, subjective, operator dependent, time-consuming and closely linked with the device performance. Another drawback is given unsatisfactory exploring of deeper or overlapping gaseous structures (confluence of common iliac vein, distal segment of inferior Cava vein).

Postthrombotic syndrome and varicose disease were the most numerous indications for phlebography, there are also cases where the confounding clinical signs between two entities make arbitrary it's including into one or other class of disease, because many of varicose disease had postthrombotic syndromes, or potthrombotic syndrome developed secondary varicose disease on superficially venous system.

Phlebography examination is higher sensitive (ca. 28%) in detecting of characteristic changes of postthrombotic syndrome (parietal irregularities, filling gaps, absence of opacification of all vascular lumen) occurred with the smaller vessels of the lower leg (both intramuscular lakes and venous axes of calf: posterior tibial and peroneal veins).

Phlebography represent a map of the venous system easily examined, viewed, and flaunted in a treatment room, operating theater, most accessible for physician documentation than bushy, descriptive, but more complex – ultrasound examination, whose information about hemodynamic and mechanical of valves allowing for a coherent treatment strategies.

Phlebography limits of exploration due to the fact that it requires a minimally invasive maneuver usually performed on a member of edema, administration of iodinated contrast media, with its risks (anaphylaxis, shock, vasovagal reactions, renal dysfunction in patients predisposed to chronic renal failure).

It was said that is the gold standard phlebography examination of the venous system. It is difficult to appreciate which imaging methods deserve this title because if digital subtraction phlebography gives details of the morphological changes and partly related to the hemodynamic, ultrasonography is sufficient in most cases for before and after therapy evaluation of the venous system, giving superior hemodynamic data to any radio-imaging methods.

### ***Indications of conventional phlebography examination as result of this study:***

- Congenital malformation
- Anatomical variants
- Patients difficult to explore by ultrasound (profoundly vascular structures at obese persons, excessive pilosity)
- When ultrasound was inconclusive due to own technique (inadequate adjustment of speed at EUB 5500, reduced depth sensitivity combined with artifacts difficult to mitigate for X300)
- For an easier examination of upper limb veins, especially humeral vein thrombosis, axillary, cephalic and their tributaries



- Examination of arteriovenous fistulas for complications in addition for surgical correction

- Some DVT and varicose disease treatment preceding act, authorizing doctors to request for clarification of issues related to the expansion point of thrombi before thrombolysis or thrombectomy, more precise quantification of repermeabilization channels, location and trajectory of accessory saphenous, location and size of perforating veins, identifying veins for bypass.

- Edema of unspecified nature of the lower limb phlebography and lymphography, both are methods that can trace positive diagnosis.

***Diagnostic algorithm of patients with disorders of the venous system:***

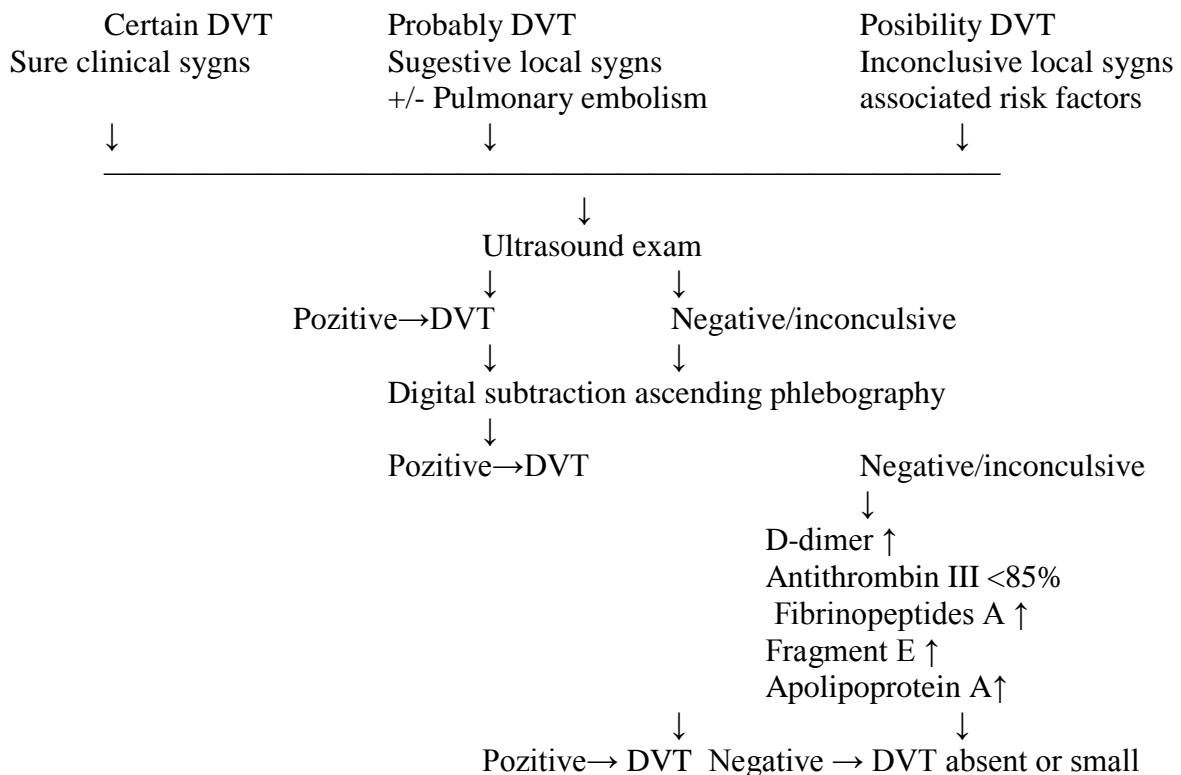
**DVT**

History should be focused on family history, personal history and on installing symptoms way. Personal history need to identify risk factors.

clinical

Laboratory methods of investigation:

Combine radio-imaging methods to measure the specific degradation products of fibrin.



In the absence of digital subtraction angiography is practiced conventional phlebography distal segments of the upper or lower limb phlebography and MRI / CT (114,115) for proximal segments, pelvis, trunk, where the contrast substance is washed quickly, carefully aiming the source images.

## References:

1. Partsch H., Editorial, *Phebolymphology*, nr. 44, 2004, 231-267;
2. Gherasim L., Pârvu V., Bolile venelor periferice, venelor cave și vaselor limfatice ale membrelor, în *Tratat de medicină internă sub redacția Păun R.*, Editura Medicală, București, 1994, partea IV, 174;
3. Gherasim L., Pârvu V., Bolile venelor, în *Medicină internă sub redacția Gherasim L.*, vol. II, Editura Medicală, București, 1996, 1067-1071;
4. Sinelnikov R. D., *Atlas de anatomie umana*, vol II, Ed. Mir, Moscova, 1989 374-465;
5. Meyer G. T., *Histology on line*, University of western Australia, 2008;
6. Saunders P. C., si colab., Vein graft arterializations causes differential activation of mitogen-activated protein kinases, *J. Thorac. Cardiovasc Surg.* 2004;127:1276-1284;
7. Guyton C. Arthur, *Fiziologie*, ediția a V-a, Editura Medicală Amaltea București sub licență W. B. Saunders, 1996, 104-117, 180-187;
8. Intaglietta M., Zweifach W. B. "Microcirculation basis in fluid exchange" *bio.med.phis.* 1974; 11:111;
9. Landis E. M., Pappenheimer J. R. Exchange of substances through the capillary wall. In: *Handbook of Physiology Circulation*. Washington: Am Physiol Soc 1963;
10. Grama M., *Fiziologie*, vol. I, Editura Hermann Press, Sibiu, 1994, 30-42;
11. Manville N., Discuss the importance of the Frank-Starling mechanism and discuss the balancing between the cardiac and vascular function curves, *Campus Medicine*, 214, 2008;
12. Pop D. Popa I., Socoteanu I., Fiziopatologia circulației venoase, în *Fiziologia și fiziopatologia hemodinamicii*, sub redacția Teodorescu-Exarcu I., Editura Medicală, București, 1985, 920;
13. Brînzeu P., Gavrilesco Șt., *Angiografia în practica medicală*, Ed. Facla, 1977, 185 – 225;
14. Reinharez D. Pigmentation following sclerosis. *Phlebologie* 1983;36: 337-344;
15. Gerson L., "The Treatment of Varicose Veins, A Critical Study of Choice of Method", *Angiology, The Journal of Vascular Diseases*, vol. 13, No. 16, 1962 pp. 260-264;
16. Malan E, Puglionisi A Congenital angiodyplasias of the extremities. Note I. Generalities and classification: venous dysplasias. *J Cardiovasc Surg* 5:239:87-130;
17. Lev M, Saphir O. Endophlebohypertrophy and phlebosclerosis. I. The popliteal vein. . *AMA Arch Pathol.* 1951;51:154–178;
18. Harrison - *Principii de Medicina internă* ed. 14, Editura Teora Bucuresti 2003;
19. Meissner M. H., Strandness E., Pathophysiology and natural history of acute deep venous thrombosis, *Rutherford's Vascular Surgery.* 2005;
20. Thomas D. P., Merton R. E., Hockley D. J., The effect of stasis on the venous endothelium: an ultrastructural study. *Br J Haematol.* Sep 1983; 55(1):113-22.
21. Anderson F. A. Jr., Wheeler H. B., Goldberg R. J., et al. The prevalence of risk factors for venous thromboembolism among hospital patients. *Arch Intern Med.* Aug 1992;152(8):1660-4
22. Schafer A. I., Hypercoagulable states: molecular genetics to clinical practice. *Lancet.* Dec 24-31 1994;344(8939-8940):1739-42;

23. Dahlback B. Inherited thrombophilia: resistance to activated protein C as a pathogenic factor of venous thromboembolism. *Blood*. Feb 1995; 85(3): 607-14;
24. Weitz J. I., Middeldorp S., Geertz W., et al. Thrombophilia and anticoagulation drugs. *American Society of Hematology Education Book*. 2004;
25. Leizorovicz A, Haugh M. C., Chapuis F. R., et al. Low molecular weight heparin in prevention of perioperative thrombosis. *BMJ*. Oct 17 1992;305(6859):913-20;
26. Kahn S., et others, Determinants and Time Course of the Postthrombotic Syndrome after Acute Deep Venous Thrombosis, *Annals of Internal Medicine*, 18 November 2008 | Volume 149 Issue 10 | 698-707;
27. Barbara Binder; Helmut Karl Lackner; Wolfgang Salmhofer; Susanne Kroemer; Jasmina Custovic; Rainer Hofmann-Wellenhof, Association Between Superficial Vein Thrombosis and Deep Vein Thrombosis of the Lower Extremities, *Arch Dermatol* 2009; 145: 753-757;
28. Forsea D., Popescu R., Popescu C. M., Compendiu de dermatologie și venerologie, Editura Tehnică, București, 1998, 258-267;
29. Cohen B. A., Lehmann C. U., *Derm Atlas online*, John Hopkins University, 2009;
30. Craig F., Weiss R., Venous Insufficiency, *e-Medicine*, 1.10.2004;
31. Lee D. C., Mann K. G., *Blood*, 1987, 70, suppl. 1, 361;
32. Perdue G. D. Jr., Smith R. B. III, Diseases of peripheral veins and the venae cavae, in *The heart*, red. Hurst J. W., V-th edition, McGraw-Hill Book Company, New York, 1982, 1508.
33. D. Boda, G. Bucur, Letitia Bucur, Adriana Diaconeasa, Tania Cristodulo, H. Rus, Sanda Marta Popescu, Calcinoza flebotatica - aspecte clinice, diagnostic si tratament, *EMCB*, 2003;
34. Bolosiu H. D., *Semiologie Medicala*, editura MEDEX Cluj Napoca, 1997,
35. Deac M., Boloșiu H. D., Manițiu I., *Semiologia aparatului cardiovascular*, Tiparul Tipografiei Eparhiale Sibiu, 1994, 77-81;
36. Angelescu N., *Tratat de patologie chirurgicala*, Editura Medicala, Bucuresti, 2001, 2224-2262;
37. Ivan V., Clasificări în patologia venoasă a membrilor inferioare, *Revista română de flebologie*, nr. 1, 2003, 46-49;
38. Badea R.I., Duda S. M., Mircea A. P. si colab., *Tratat de ultrasonografie clinica*, vol. I - III, Ed. Medicala, Bucuresti, 2006;
39. Brkljacic B., Bozidar S., Ante G., Leonardo P., Andrija H., Color duplex Ultrasonography of lower extremities veins types of findings, *Radiol. Oncol.*, 2001, 35(2): 83-8;
40. Birdwell B. G., Raskob G. E., Whitsett T. L., Durica S. S., Comp P. C., George J. N., et al. Clinical validity of normal compression ultrasonography in outpatients suspected of having deep vein thrombosis. *Ann Intern Med* 1998;128: 1-7;
41. Rose S. C., Zwiebel W.J., Nelson B. D., Symptomatic Lower Extremity Deep Venous Thrombosis: Accuracy, Limitations and Role of Color Duplex Flow Imaging in Diagnosis – *Radiology*, 1990, 175: 639-645;
42. Lensing A. W .A., Prandoni P, Buller H. R., Casara D., Cogo A., Cate J. W., Lower extremity venography with iohexol: results and complication. *Radiology* 1990;177:503–5;
43. Redman H. C., Deep venous thrombosis: is contrast venography still the diagnostic gold standard? *Radiology* 1988;168:277–8;
44. Suresh Vedantham, Deep Venous Thrombosis: The Opportunity at Hand, *American Journal of Roentgenology*, *AJR* 2009; 193:922-927;

45. Kinmonth JB. The lymphatics: diseases, lymphography and surgery. London: Edward Arnold Ltda; 1972
46. Pillari G., Zito J., Chang J. B., Cohen JR, Greenspan B., Gersten K., et al. Lower extremity swelling: computerized tomography following negative venography. *Cardiovasc Intervent Radiol* 1987; 10:261-3;
47. Stehling M. K., Rosen M. P., Weintraub J., Kim D., Raptopoulos V., Spiral CT venography of the lower extremity. *AJR* 1994;163:451-3;
48. Shah A. A., Buckshee N, Yankelevitz D. F., Henschke C. I. Assessment of deep venous thrombosis using routine pelvic CT. *AJR* 1999;173:659-63;
49. Spritzer C. E., Arata M. A., Freed K. S., Isolated pelvic deep venous thrombosis: relative frequency as detected with MR imaging. *Radiology* 2001;219:521-5;
50. Para J. E., Mora F., Villegas G., Romero-Vecchione E., Vasquez J., Desarrollo de un pletismografo de impedancia para evaluar la hiperemia reactiva en el antebrazo, *Acta Cientifica Venezolana*, 2003, 54:2-11;
51. Tovey C., *Radiology of Deep Vein Thrombosis*, [bmj.com](http://bmj.com), 3 Jun 2003
52. Ginsberg J. S., Kearon C., Douketis J., Turpie A. G., Brill-Edwards P., Stevens P., et al. The use of D-dimer testing and impedance plethysmographic examination in patients with clinical indications of deep vein thrombosis. *Arch Intern Med* 1997;157: 1077-81;
53. Kelly J., Rudd A., Lewis R. R., Hunt B. J., Plasma D-dimers in the diagnosis of venous thromboembolism. *Arch Int Med* 2002;162: 747-56;
54. Pittet J. L., de Moerloose P., Reber G., Durand C., Villard C., Piga N., et al. VIDAS D-dimer: fast quantitative ELISA for measuring D-dimer in plasma. *Clin Chem* 1996;42: 410-5;
55. Wells P. S., Brill-Edwards P., Stevens P., Panju A., Patel A., Douketis J., et al. A novel and rapid whole-blood assay for D-dimer in patients with clinically suspected deep vein thrombosis. *Circulation* 1995;91: 2184-7;
56. Wells P. S., Anderson D. R., Rodger M., Forgie M., Kearon C., Dreyer J., et al. Evaluation of D-dimer in the diagnosis of suspected deep-vein thrombosis. *N Engl J Med*. Sep 25 2003;349(13):1227-35.
57. Hirsh J., M. D.; Hoak J., *Management of Deep Vein Thrombosis and Pulmonary Embolism*, *Circulation*, 1996; 93:2212-2245;
58. Kirsten R. L., Surgical repair of a venous valve, *Straub Clin. Proc.*, 1968, 34, 41-43;
59. Joffe HV, Kucher N, Tapson VF, Goldhaber SZ. Upper-extremity deep vein thrombosis: a prospective registry of 592 patients. *Circulation*. Sep 21 2004;110(12):1605-11 Wilson, N. M., Rutt, D. L. and Browse, N. L. (1991), In situ venous valve construction. *British Journal of Surgery*, 78: 595-600. doi: 10.1002/bjs.1800780525
60. Rhodes JM, Cho JS, Gloviczki P, Mozes G, Rolle R, Miller VM. Thrombolysis for experimental deep venous thrombosis maintains valvular competence and vasoreactivity. *J Vasc Surg*. Jun 2000;31(6):1193-205.
61. Michota F, Merli G. Anticoagulation in special patient populations: are special dosing considerations required?. *Cleve Clin J Med*. Apr 2005;72 Suppl 1:S37-42.
62. McGarray LJ, Stokes ME, Thompson D. Outcomes of Thromboprophylaxis with enoxaparin vs. Unfractionated Heparin in Medical Inpatients: A Retrospective Database Analysis. *Thromb J*; 2006:Sep 27;4(1):17.
63. Stephen Th., *Compression bandaging in the treatment of venous leg ulcers*, *World Wide Wounds*, sep. 1998;
64. Proebstle T. M., Sandhofer M., Kargl A., Gul D., Rother W., Knop J., Thermal damage of the inner vein wall during endovenous laser treatment: key role of energy absorption by intravascular blood. *Dermatol Surg*. Jul 2002;28(7):596-600

65. Mordon S. R., Wassmer B., Zemmouri J., Mathematical modeling of endovenous laser treatment (ELT). *Biomed Eng Online*. 2006;5:26
66. Anderson R. R., Endovenous Laser: Mechanism of Action. Presented at the Annual Meeting of the American Academy of Dermatology. San Francisco, California, USA. March 3-7, 2006.
67. Disselhoff B. C., Rem A. I., Verdaasdonk R. M., Kinderen D. J., Moll F. L., Endovenous laser ablation: an experimental study on the mechanism of action. *Phlebology*. 2008;23(2):69-76
68. Khilnani N. M., Grassi C. J., Kundu S., D'Agostino H. R., Khan A. A., McGraw J.K., Multi-society consensus quality improvement guidelines for the treatment of lower-extremity superficial venous insufficiency with endovenous thermal ablation from the Society of Interventional Radiology, Cardiovascular Interventional Radiological Society of Europe, American College of Phlebology and Canadian Interventional Radiology Association. *J Vasc Interv Radiol*. Jan 2010;21(1):14-31.
69. Timperman P. E., Sichlau M., Ryu R. K., Greater energy delivery improves treatment success of endovenous laser treatment of incompetent saphenous veins. *J Vasc Interv Radiol*. Oct 2004;15(10):1061-3
70. Desmyttere J, Grard C, Wassmer B, Mordon S. Endovenous 980-nm laser treatment of saphenous veins in a series of 500 patients. *J Vasc Surg*. Dec 2007;46(6):1242-7.
71. Proebstle T. M., Gul D., Lehr H. A., Kargl A., Knop J. Infrequent early recanalization of greater saphenous vein after endovenous laser treatment. *J Vasc Surg*. Sep 2003;38(3):511-6.
72. Almeida J. I., Raines J. K. Radiofrequency ablation and laser ablation in the treatment of varicose veins. *Ann Vasc Surg*. Jul 2006;20(4):547-52
73. Almeida J. I., Kaufman J., Göckeritz O., Chopra P., Evans M. T., Hoheim D. F., et al. Radiofrequency endovenous ClosureFAST versus laser ablation for the treatment of great saphenous reflux: a multicenter, single-blinded, randomized study (RECOVERY study). *J Vasc Interv Radiol*. Jun 2009;20(6):752-9.
74. Puggioni A., Kalra M., Carmo M., Mozes G., Gloviczki P., Endovenous laser therapy and radiofrequency ablation of the great saphenous vein: analysis of early efficacy and complications. *J Vasc Surg*. Sep 2005;42(3):488-93
75. Mekako A. I., Hatfield J., Bryce J., Lee D., McCollum P. T., Chetter I., A nonrandomised controlled trial of endovenous laser therapy and surgery in the treatment of varicose veins. *Ann Vasc Surg*. Jul 2006;20(4):451-7.
76. Rasmussen L. H., Bjoern L., Lawaetz M., Blemings A., Lawaetz B., Eklof B. Randomized trial comparing endovenous laser ablation of the great saphenous vein with high ligation and stripping in patients with varicose veins: short-term results. *J Vasc Surg*. Aug 2007;46(2):308-15.
77. Zwiebel J. W., Extremity venous examination: Technical Considerations-in: Zwiebel W.J., Introduction to Vascular Ultrasonography, W.B. Saunders Co, Philadelphia, 2000; 311-327;
78. C.A.D Leguy, E.M.H Bosboom, A.P.G Hoeks, R.N Planken, F.N. van de Vosse, Assessment of local blood pressure and flow in arteries using ultrasound
79. Opie J. C., Sos P. J., Izdebski Th., Shacket R., Alpern J., Umer A., An Autogenous Solution for Chronic Venous Insufficiency, *Vascular Disease Management*, vol. 7, oct. 2011, 204-209
80. Brand F. N., Dannenberg A. L., Abbott R. D., Kannel W. B., The epidemiology of varicose veins: the Framingham Study, *Am J Prev Med*. 1988 Mar-Apr;4(2):96-101;

81. Carpentier P. H., Maricq H. R., Biro C., Ponçot-Makinen C. O., Franco A., Prevalence, risk factors, and clinical patterns of chronic venous disorders of lower limbs: a population-based study in France, *J Vasc Surg.* 2004 Oct;40(4):650-9;
82. Chiesa R., Marone E. M., Limoni C., Volonté M., Schaefer E., Petrini O., Chronic venous insufficiency in Italy: the 24-cities cohort study, *Eur J Vasc Endovasc Surg.* 2005 Oct; 30(4):422-9;
83. Nick J. M. London, Roddy Nash, Varicose veins, *BMJ* 320 : 1391 doi: 10.1136/bmj.320.7246.1391 (Published 20 May 2000);
84. Andrew T., Spector T. D., Linkage to the FOXC2 region of chromosome 16 for varicose veins in otherwise healthy, unselected sibling pairs, *Journal of Medical Genetics*, 2005, vol. 42, no3, pp. 235-239
85. Blanchemaison P. H., Grenay P. H., Camponovo J., Atlas de anatomía de las venas superficiales del miembro inferior. Volumen II: El territorio de la vena safena interna. Publicaciones Médicas de Laboratorios Servier; Madrid, 1997. Pag: 5-47.
86. Tsai S., Dubovoy A., Wainess R., Severe chronic venous insufficiency: magnitude of the problem and consequences. *Ann Vasc Surg.* 2005;19:705-11.
87. Ciucci J. L., Amore M. A., Casal F., Iroulart J. A., Variaciones anatomica del arco de la vena safena magna, *Revista Argentina de Anatomía Online* 2010 (Julio – Agosto – Septiembre), Vol. 1, Nº 3, pp. 81 – 116.
88. Jesús Sánchez. Bases Anatómicas para la Disección Quirúrgica de los Cayados Safenos. El Confluente Safenofemoral. *Anales de Cirugía Cardíaca y Vasculiar* 2000; 6 (2) : 72 – 79.
89. Fischer R., Fulleman N.H., Alder W. A propos d'un dogme phlébologique sur les localisations des perforantes de Cockett. *Phlébologie* 1992; 45: 207-12.
90. Gillot C. Anatomie chirurgicale des perforantes de la jambe. *Phlébologie* 1987; 40: 563-74.
91. Staubesand J., Stemmer R. Études anatomiques sur la constance des perforantes de Cockett. *Phlébologie* 1987; 40: 599-604.
92. Baun Jim, Communicating (perforator) Veins, The Prosono Library online, 2006
93. Wesley P. Stuart, Donald J. Adam, Paul L. Allan, C.Vaughan Ruckley, Andrew W. Bradbury: The relationship between the number, competence, and diameter of medial calf perforating veins and the clinical status in healthy subjects and patients with lower-limb venous disease, *Journal of Vascular Surgery*, Volume 32, Issue 1, July 2000, Pages 138-143
94. Labropoulos N, Mansour M. A., Kang S. S., et al. New insights into perforator vein incompetence. *Eur J Vasc Endovasc Surg.* 1999 Sep; 18(3):228-34.
95. Stuart W. P., Lee A. J., Allan P. L., et al. Most incompetent calf perforating veins are found in association with superficial venous reflux. *J Vasc Surg.* 2001 Nov; 34(5):774-8.
96. Leguy C. A., Bosboom E. M., Hoeks A. P., Van de Vosse F. N., Assessment of blood volume flow in slightly curved arteries from a single velocity profile
97. Lutter K. S., Kerr T. M., Roedersheimer L. R., et al., Superficial thrombophlebitis diagnosed by duplex scanning. *Surgery.* Jul 1991;110(1):42-6
98. Johnson G., DePalma R. G., Superficial thrombophlebitis: diagnosis and management. In: *Rutherford's Vascular Surgery.* Vol 1. 5th ed. Philadelphia, Pa: WB Saunders; 1998:1979, section XIX
99. Marc D. Silverstein; John A. Heit; David N. Mohr; Tanya M. Petterson; W. Michael O'Fallon; L. Joseph Melton III, Trends in the Incidence of Deep Vein Thrombosis and Pulmonary Embolism, *Arch Intern Med.* 1998;158:585-593;

100. Kaushal (Kevin) Patel; Barry E Brenner, Deep Venous Thrombosis, Medscape, 16.11.2011
101. Useche J. N., de Castro A. M., Galvis G. E., Mantilla R. A., Ariza A., Use of US in the evaluation of patients with symptoms of deep venous thrombosis of the lower extremities. *Radiographics*. Oct 2008;28(6):1785-97.
102. SEVITT S, GALLAGHER N. Venous thrombosis and pulmonary embolism. A clinico-pathological study in injured and burned patients. *Br J Surg*. Mar 1961;48:475-89.
103. Prandoni P., Mannucci P. M., Deep-vein thrombosis of the lower limbs: diagnosis and management. *Baillieres Best Pract Res Clin Haematol*. Sep 1999;12(3):533-54.
104. Killewich L. A., Bedford G. R., Strandness D. E., Duplex Scanning in the Diagnosis of Deep Venous Thrombosis: Limitations and Methods for Improving Diagnostic Accuracy-Dinamic Cardiovascular Imaging, 1989; 33-38.
105. Douzat M., *Ultrasonographie vasculaire diagnostique: Theorie et Practique* – Ed. Vigot, Paris, 1995
106. Douzat M., Laroche J. P., De Bray J. M., Deklunder G., Winsberg F., Duplex and Colour- Coded Doppler Examination for the Diagnosis of Lower Limb Veins and Arteries – in: Labs K. H., Jager K. A., Fitzgerald D. E., Woodcock J. P., Neuerburgheusler D., *Diagnostic Vascular Ultrasound*, Edward Arnold, London, 1992: 183-209
107. Keogan M. T., Paulson E. K., Paine S. S., Hertzberg B. S., Carroll B.A., Bilateral Lower extremity Evaluation of Deep Venous Thrombosis with Color Flow and Compression Sonography- *J. Ultrasound Med.*, 1994; 13:115-118
108. Prandoni P., Prins M. H., Lensing A. W., Ghirarduzzi A., Ageno W., Imberti D., et al. Residual thrombosis on ultrasonography to guide the duration of anticoagulation in patients with deep venous thrombosis: a randomized trial. *Ann Intern Med*. May 5 2009;150(9):577-85.
109. Baxter G. M., Duffy P., MacKechnie S., Colour Doppler ultrasound of the post-phlebotic limb: Sounding a cautionary note, *Clinical Radiology*, Volume 43, Issue 5, Pages 301-304
110. Sevitt S., The mechanisms of canalisation in deep vein thrombosis. *J Pathol*. Jun 1973;110(2):153-65.
111. Monreal M., Martorell A., Callejas J. M., Valls R., Llamazares J. F., Lafoz E., et al. Venographic assessment of deep vein thrombosis and risk of developing post-thrombotic syndrome: a prospective study. *J Intern Med*. Mar 1993;233(3):233-8.
112. Neglen P., Raju S. A., comparison between descending phlebography and duplex Doppler investigation in the evaluation of reflux in chronic venous insufficiency: a challenge to phlebography as the "gold standard". *J Vasc Surg*. Nov 1992;16(5):687-93.
113. Coche E. E., Hamoir X. L., Hammer F. D., Hainaut P., Goffette P. P., Using dual-detector helical CT angiography to detect deep venous thrombosis in patients with suspicion of pulmonary embolism: diagnostic value and additional findings. *AJR Am J Roentgenol*. Apr 2001;176(4):1035-9
114. Li W, Salanitri J., Tutton S., Dunkle E. E., Schneider J. R., Caprini J. A., et al. Lower extremity deep venous thrombosis: evaluation with ferumoxytol-enhanced MR imaging and dual-contrast mechanism--preliminary experience. *Radiology*. Mar 2007;242(3):873-81.
115. Schiff R. L., Kahn S. R., Shrier I., Strulovitch C., Hammouda W., Cohen E., et al. Identifying orthopedic patients at high risk for venous thromboembolism despite thromboprophylaxis. *Chest*. Nov 2005;128(5):3364-71.
116. Ginsberg J. S., Turkstra F., Buller H. R., MacKinnon B., Magier D., Hirsh J., Postthrombotic syndrome after hip or knee arthroplasty: a cross-sectional study. *Arch Intern Med*. Mar 13 2000;160(5):669-72

117. Arfvidsson B., Eklof B., Kistner R.,L., Masuda E. M., Sato D. T., Risk factors for venous thromboembolism following prolonged air travel. Coach class thrombosis. *Hematol Oncol Clin North Am.* Apr 2000;14(2):391-400, ix.
118. Monreal M., Lafoz E., Casals A., Inaraja L., Montserrat E., Callejas J. M., et al. Occult cancer in patients with deep venous thrombosis. A systematic approach. *Cancer.* Jan 15 1991;67(2):541-5.
119. Rickles F. R., Levine M., Edwards R. L., Hemostatic alterations in cancer patients. *Cancer Metastasis Rev.* Nov 1992;11(3-4):237-48.
120. Levine M. N., Gent M., Hirsh J., Arnold A., Goodyear M. D., Hryniuk W., et al. The thrombogenic effect of anticancer drug therapy in women with stage II breast cancer. *N Engl J Med.* Feb 18 1988;318(7):404-7.
121. Korelitz B. I., Sommers S. C., Responses to drug therapy in ulcerative colitis. Evaluation by rectal biopsy and histopathological changes. *Am J Gastroenterol.* Nov 1975;64(5):365-70.
122. Vandenbrouke J. P., Bloemenkamp K. W., Rosendaal F. R., Helmerhorst F. M., Incidence of venous thromboembolism in users of combined oral contraceptives. Risk is particularly high with first use of oral contraceptives. *BMJ.* Jan 1 2000;320(7226):57-8.
123. Gasparis A. P., Tsintzilonis S., Labropoulos N., Extraluminal lipoma with common femoral vein obstruction: a cause of chronic venous insufficiency. *J Vasc Surg.* Feb 2009;49(2):486-90.